

Ce cours a été approuvé par l'Ordre des Optométristes du Québec pour un (1) crédit UFC de catégorie A en santé oculaire, à la condition que le questionnaire à la fin de cet article soit complété et soumis en ligne ou par courrier au plus tard le 31 mars 2024. Il n'y a aucun coût pour accéder à cet article ou le télécharger, mais des frais de 25 \$ s'appliqueront pour noter le questionnaire et transmettre un certificat UFC personnalisé. Les détails du processus de soumission sont inclus dans le questionnaire.

## Ocular Cicatricial Pemphigoid: A Case Report

Reena A. Patel, OD

### ABSTRACT

**Purpose:** The aim of this Case Report is to explain the effect of undiagnosed ocular cicatricial pemphigoid (OCP), the importance of early diagnosis, and the management of OCP. **Method:** This article will use a 53-year-old white male with a history of chronic conjunctivitis to help illustrate OCP. **Result:** The exam findings revealed inferior temporal symblepharon and granulomas on the palpebral conjunctiva of both eyes. Once biopsies of the eyelid growths led to a definitive diagnosis of OCP, the patient was treated orally with 60 mg of prednisone daily. Future treatment options include the use of immunosuppressive drugs. **Conclusion:** OCP is frequently diagnosed in advanced stages. Therefore, aggressive treatment is often necessary. As optometrists, our goal is to recognize this condition as early as possible and to initiate treatment before vision loss occurs.

### INTRODUCTION

Ocular cicatricial pemphigoid (OCP), also known as mucous membrane pemphigoid with ocular involvement, is an ocular surface disease with one of the worst visual outcomes.<sup>1</sup> Ocular cicatricial pemphigoid is part of a range of systemic disorders termed mucous membrane pemphigoid (MMP).<sup>2</sup> Mucous membrane pemphigoid encompasses a group of chronic, inflammatory, and subepithelial autoimmune diseases of the mucous membranes. It is characterized by a linear deposit of specific immunoglobulins or complement 3 that are found along the epithelial basement membrane zone (BMZ).<sup>3</sup> Scarring is a clinical hallmark of these conditions.<sup>3</sup> MMP lesions are most commonly found in the mucosa of the mouth (85%) and in the conjunctiva of the eye (64%). It

can also involve the nose, pharynx, skin, larynx, and esophagus.<sup>4</sup> Of the patients with oral involvement it is estimated that 15% to 20% will develop ocular involvement within five years of onset.<sup>5</sup> Clinical features of OCP include bilateral, asymmetric, chronic progressive or relapsing inflammation, ulceration, and opacification of the cornea leading to a decrease in vision.<sup>4</sup>

Ocular cicatricial pemphigoid is a rare condition generally found within the population of individuals aged sixty to eighty years old; however a few cases have been reported in young children.<sup>6</sup> Annual incidence has been reported as 1:20,000 to 1:46,000 ophthalmic cases.<sup>7</sup> Research suggests that there is a genetic predisposition for the condition, however, triggering factors for the onset of OCP are unknown.<sup>8</sup> OCP is not contagious and cannot be transmitted from person-to-person.<sup>9</sup> There is a 2:1 predilection for females versus males, but no racial or ethnic predilection has been shown. The frequency in the United States is unknown.

### CASE REPORT

A 53-year-old Caucasian male reported to the clinic with a chief complaint of ocular irritation for eight months. He reported ocular irritation occurring in the corner of both eyes and of "blister-like" sensations underneath his eyelids. The eyes were also reported to be crusted shut every morning. The patient self-treated with artificial tears every 10 minutes, but reported little relief. Medical history included osteoarthritis, asthma, and allergic rhinitis. He was taking the following systemic medications: albuterol, divalproex, docusate, flunisolide, fluocinolone, loratadine, omeprazole, sennosides, and trazodone.

Best corrected visual acuities were 6/7.5 (20/25) in the right eye and 6/12 (20/40) in the left eye. Examination of the lids and lashes revealed flaking and crusting. In the inferior temporal palpebral conjunctiva of both eyes, mild symblepharon were noted. Slit lamp evaluation also indicated mild bulbar conjunctival injection and two distinct, non-ulcerated growths that were smooth and firm upon palpation on the superior palpebral conjunctiva of both eyes. The corneas in both eyes had mild, superficial punctate keratitis and a central scar was noted in the left cornea. Dilated fundus examination was unremarkable.

---

R.A. Patel — Family Vision Care of Rutherford, Rutherford, NJ Correspondence to: Dr. Reena A. Patel, Family Vision Care of Rutherford, 31 Park Avenue, Rutherford, NJ 07070; E-mail: ragarw1@gmail.com This article has been peer-reviewed.

with the exception of anterior cortical cataracts and nuclear sclerotic cataracts in both eyes. The patient was educated to remain on artificial tears and was referred to a corneal specialist for further evaluation. The patient was started on Restasis™ (Allergan, Irvine, CA), prednisolone acetate 1% (4.4), cromolyn 4% (4.4) ketotifen 0.035% (4.4), and Tobradex™ (Alcon, Fort Worth, TX) ointment at bedtime OU. Punctal plugs were also inserted inferiorly in both eyes. The patient was then referred to oculoplastics for a conjunctival biopsy. Based on the biopsy, clinical signs, and patient history, the patient was diagnosed with ocular cicatricial pemphigoid. In order to determine if the patient had other forms of MMP, he was referred to the dermatologist and dentist for further evaluation.

The dermatology report indicated that scars and post-inflammatory hyperpigmentation were found on different areas of the body. At the time of the examination new blisters were not evident. Therefore, skin biopsies could not be conducted. The patient did, however, report previous episodes of developing blisters on his face, arms, back, legs, and buttocks.

Final treatment based on the diagnosis of ocular cicatricial pemphigoid was 60 mg of oral prednisone daily for one week. Due to the severity of the disease, treatment in the future could include immunosuppressive therapy.

## **PATHOGENESIS**

The human body is naturally protected by its immune system.<sup>5</sup> When the immune system functions properly it produces antibodies to attack foreign bacteria or viruses. Patients with OCP have an immune system that malfunctions, causing the body's natural proteins to be seen as foreign and subsequently attacked.<sup>5</sup> OCP is considered a subepithelial disorder because the anchoring proteins keeping the epithelium and its underlying stroma attached are attacked.<sup>4</sup> Specifically, the autoantibodies attack the anchoring proteins in the hemidesmosomes and the basement membrane zone of the mucosa.<sup>7,8</sup> When the proteins are attacked, the skin cells become separated and blisters develop.<sup>5</sup> As the blisters heal, fibrosis and scarring of the tissue occurs.<sup>5</sup>

The progressive fibrotic nature of OCP causes destructive changes to the ocular surface. Such changes include fornix shortening, symblepharon formation, destruction of goblet cells, and eyelid margin deformities.<sup>1</sup> Such deformities include entropion, trichiasis, dystichiasis, and lagophthalmos.<sup>7</sup> Damage to the eyelid margin can lead to obstruction of lacrimal and meibomian duct orifices.<sup>1</sup> All these changes can lead to a decrease in production and excess evaporation of tears, therefore leading to severe dry eye.<sup>1</sup> Severe dry eye can cause corneal ulcers, scars, abrasions, and neovascularization.<sup>7</sup> Together with fornix shortening, symblepharon, and severe dry eye, vision loss can occur.

## **DIAGNOSIS**

Patients with OCP will present with complaints of burning, redness, tearing, decreased vision, and foreign body sensation.<sup>6</sup> When undiagnosed, these patients will have a chronic history of continual conjunctivitis or dry eye. These are the patients who have seen multiple practitioners and who have tried multiple ocular medications, but found little relief. These are also the patients who need to be evaluated further for the possibility of other ocular surface disease. Possible differential diagnoses include: atopic keratoconjunctivitis, trachoma, trauma, chemical burn, Stevens-Johnson syndrome, sarcoidosis, and drug-induced pseudopemphigoid.<sup>4,9</sup> Most of the differentials stated above can be eliminated by a thorough case history. If the diagnosis of OCP is being considered, a conjunctival biopsy using the direct immunofluorescence (DIF) test must be obtained.<sup>5,10</sup> This technique involves examining a conjunctival specimen for the presence of autoantibodies.<sup>11</sup> The specimen to be biopsied is obtained from the tissue adjacent to the inflamed site.<sup>7</sup> For a definitive diagnosis of OCP a linear deposition of immunoreactants, usually IgG, IgA, and the third component of complement, at the basement membrane of an inflamed conjunctiva is necessary.<sup>10</sup> DIF testing is the gold standard for the diagnosis of OCP.<sup>10</sup> The sensitivity of the test is decreased when confirming OCP versus other testing for MMP from other mucosal sites.<sup>11</sup> As a result, a negative biopsy does not exclude OCP, but a positive biopsy confirms the diagnosis.<sup>7</sup> This can be problematic when considering starting a patient on treatment if a confirmed diagnosis is not available.<sup>11</sup> A conjunctival biopsy must be performed, however, even with a negative result, OCP can be diagnosed and treated. OCP is not easy to diagnose, but it is a condition that should be on the list of differential diagnoses.

Once diagnosed as OCP, the disease is staged and graded using either Foster's or Mondino's classification system. Staging the disease helps with treatment and with predicting the progression of the condition. Foster's system includes four stages. Stage one involves conjunctival injection, scarring, and fibrosis.<sup>7,12</sup> Stage two begins with the foreshortening of the inferior conjunctival cul-de-sac of any degree.<sup>7,12</sup> This leads to the formation of a symblepharon which is described as stage three.<sup>7,12</sup> Stage three also includes such signs as corneal neovascularization, keratopathy, trichiasis, entropion, dystichiasis, and decreased tear production.<sup>7</sup> Stage four is considered the end stage of OCP and results in ankyloblepharon and ocular surface keratinization which can lead to blindness.<sup>7,9</sup> Mondino grades OCP based on loss of inferior fornix depth. Stage one is 0 to 25% loss, stage two is 25% to 50% loss, stage three is 50% to 75% loss, and stage four is 75% to 100% loss of inferior fornix depth.<sup>13</sup> Stages three and four in both Foster's and Mondino's classification system are considered advanced stages.

## TREATMENT

The goal of treatment is to prevent inflammation and scarring, reduce recurrences, decrease symptoms, and ultimately, preserve vision.<sup>2</sup> There is no gold standard for treatment, but current treatment approaches consist of oral corticosteroids or immunosuppressives, intravenous medications such as immunoglobulin (IVIg) therapy, and/or subcutaneous injections of anti-tumor necrosis factor alpha (TNF- $\alpha$ ) agents. Treatment is based on each individual, as the disease is highly variable and may affect different areas of the body. Before initiating ocular treatment, it is also important to determine if non-ocular sites are involved and the stage, progression, and probable duration of the disease.<sup>7</sup> Due to the systemic etiology of OCP, topical and subconjunctival treatment with corticosteroids, cyclosporine, and retinoids are ineffective in controlling ocular inflammation.<sup>14</sup> However, artificial tears are still recommended.<sup>15</sup> Once the diagnosis of OCP is confirmed, acceptable first-line therapy includes immunosuppressive medications with or without corticosteroids.<sup>14,15</sup>

Most patients are diagnosed in advanced stages, thus aggressive treatment is indicated. Initially, high doses of oral corticosteroids are administered to prevent further scarring, but steroids alone will not fully control the disease.<sup>11,16,17</sup> Patients must remain on the steroid for a long period of time and because of long-term complications, it is an undesirable treatment option.<sup>18</sup> Patients have also been found to have recurrences during the tapering period of the steroid.<sup>19</sup> Current therapy typically begins with administering oral corticosteroids to rapidly inhibit further scarring, and then the steroid is completely tapered or decreased in dosage. During the tapering period, oral immunosuppressive drugs may be added to the treatment plan.<sup>14,15</sup> Immunosuppressive medications include methotrexate, cyclophosphamide, mycophenolate mofetil (Cellcept<sup>TM</sup>), diaminodiphenylsulfone (Dapsone<sup>TM</sup>), and azathioprine.<sup>20</sup> The recommended dosage of oral prednisone that has been found to be effective in rapidly ceasing scarring is 1 mg/kg daily.<sup>21,22</sup> Studies have reported that for severe ocular disease, the combination of cyclophosphamide and prednisone has been found to be the most effective in controlling the disease.<sup>23,24</sup> Treatment normally consists of 2 mg/kg daily of oral cyclophosphamide with 1 mg/kg of oral prednisone daily.<sup>25</sup> The prednisone will be tapered over 3 to 4 months, whereas cyclophosphamide will be continued for 12 to 18 months unless patients have contraindications or side effects.<sup>20</sup> Patients should be followed monthly.

Miserocchi et al looked at the effect of the use of immunosuppressive medications with or without prednisone on patients with severe ocular cicatricial pemphigoid. Immunosuppressive medications used in this study included: (from most commonly used to least) oral

diaminodiphenylsulfone (Dapsone<sup>TM</sup>), methotrexate, azathioprine, and cyclophosphamide. In some cases, oral prednisone was used as an adjunctive treatment. The medications were found to control ocular inflammation in 90% of the 61 patients studied, however, 46% of those patients needed to remain on a maintenance dose to prevent recurrences. Ten per cent of the 61 patients progressed regardless of different drugs used. The average length of treatment was 48 months of immunosuppressive therapy and 29 months of oral corticosteroid therapy. Side effects of immunosuppressive medications included hematologic, gastrointestinal, cardiovascular, and urinary complications. Based on this study, to control the effects of OCP, long-term systemic treatment is necessary.<sup>14</sup>

In addition to immunosuppressive therapy, case reports have demonstrated that anti-tumor necrosis factor alpha agents (TNF- $\alpha$ ) and/or intravenous immunoglobulin (IVIg) drugs are other treatment options. Cytokines, such as TNF- $\alpha$ , are soluble proteins that are released by cells. They play a role in cellular communication and in mediating cell processes such as gene expression and cell proliferation, survival, differentiation, and migration.<sup>26</sup> During an immunologic response they are responsible for initiating, maintaining, and resolving inflammation.<sup>26</sup> Different types of cytokines are produced by our bodies; immunoregulatory and proinflammatory cytokines such as interferon, interleukins, and TNF-alpha, are particularly important to the pathogenesis of OCP.<sup>12</sup> TNF- $\alpha$  is a proinflammatory cytokine produced at low levels by macrophages under normal conditions, thus maintaining cellular and tissue homeostasis.<sup>27</sup> When injury or microbial invasion occurs to the body, TNF- $\alpha$  production is increased and released by macrophages, mastocytes, keratinocytes, and fibroblasts.<sup>26</sup> TNF- $\alpha$  in turn attracts leukocytes to the injured tissue.<sup>27-30</sup> Leukocytes increase vascular permeability, allowing macromolecules such as fibrinogen, immunoglobulin, and complement to be released at the affected site.<sup>31</sup> Regulatory mechanisms, normally found in healthy individuals, prevent the overproduction of TNF- $\alpha$  and other cytokines from becoming persistent.<sup>32</sup> When large amounts of TNF- $\alpha$  are released without regulation, inflammation reactions are sustained at the site of injury leading to chronic inflammatory diseases.<sup>6,26</sup> A study done in 1993 found that the serum levels of patients with MMP when compared to controls had elevated levels of TNF- $\alpha$ .<sup>33</sup> Due to the role of TNF- $\alpha$  during inflammation, it is currently being researched for the treatment of OCP.<sup>26</sup> Today, anti-TNF- $\alpha$  agents have been used to treat psoriasis, psoriatic arthritis, rheumatoid arthritis, Crohn's disease, and ankylosing spondylitis.<sup>6</sup>

Currently there are three anti-TNF- $\alpha$  agents that have been used in the treatment of inflammatory and autoimmune diseases: infliximab, adalimumab, and etanercept.<sup>6</sup> Case Reports describe solely the use of anti-TNF- $\alpha$  agents in the treatment of OCP. Large scale studies have not been conducted. Canizanes et al report on

three patients with MMP who were successfully treated with etanercept. All three patients had oral mucosal involvement, and one had severe ocular involvement.<sup>6</sup> Of the three patients treated, all had little success with prior therapy. The patients were then treated with subcutaneous injections of 25 mg of etanercept twice weekly. In all three patients the oral mucosal disease improved and the one patient with the ocular involvement obtained stabilization.<sup>6</sup> Further investigation is required to study the safety and efficacy of anti-TNF- $\alpha$  agents in the treatment of ocular cicatricial pemphigoid.<sup>6</sup>

Intravenous immunoglobulin drugs are also used in the treatment of autoimmune conditions because of their anti-inflammatory effect.<sup>2</sup> Intravenous immunoglobulin decreases pro-inflammatory cytokines including interleukin-1 and TNF- $\alpha$  and it increases anti-inflammatory cytokines.<sup>34</sup> Letko et al. looked at immunosuppressive therapy versus intravenous immunoglobulin therapies in patients with MMP who had ocular involvement.<sup>2</sup> Results indicated that patients treated with IVIg had a more rapid control of ocular inflammation and did not progress to advanced stages of OCP, whereas patients treated with immunosuppressive therapy had multiple recurrences.<sup>2</sup> Side effects reported in this study included headaches and nausea after infusion of the drug, but these decreased if the rate of infusion was decreased.<sup>2</sup>

Progression of a disease plays a key role in the method of treatment and its expected outcome. It is especially important when treating OCP, because once conjunctival fibrosis and keratopathy has occurred it cannot be reversed and visual rehabilitation is poor.<sup>13</sup> Unfortunately due to the variable course of the disease, little is known about the progression of the disease.<sup>13</sup> OCP is characterized as a chronic and slow disease that eventually leads to bilateral blindness if left untreated.<sup>11</sup> Elder et al. looked at factors that could play a role in the progression and visual outcome of the disease. They found that there was no correlation between systemic manifestations of pemphigoid and vision loss.<sup>13</sup> It was also reported that patients with symblepharon at diagnosis were more likely to have a rapidly progressive disease with a worse visual prognosis, therefore requiring immunosuppressive therapy versus the patients who at diagnosis did not have symblepharon. They also reported that persistent epithelial defects, limbal inflammation, and conjunctival inflammation were factors that led to increased risk of vision loss.<sup>13</sup>

## DISCUSSION

This case presented a patient with a chronic history of dry eye complaints with little relief while on topical medications. Due to the lack of specific signs and symptoms of early stages of OCP, the patient was incorrectly diagnosed with dry eye and chronic conjunctivitis. Ocular cicatricial pemphigoid is a rare disease, but

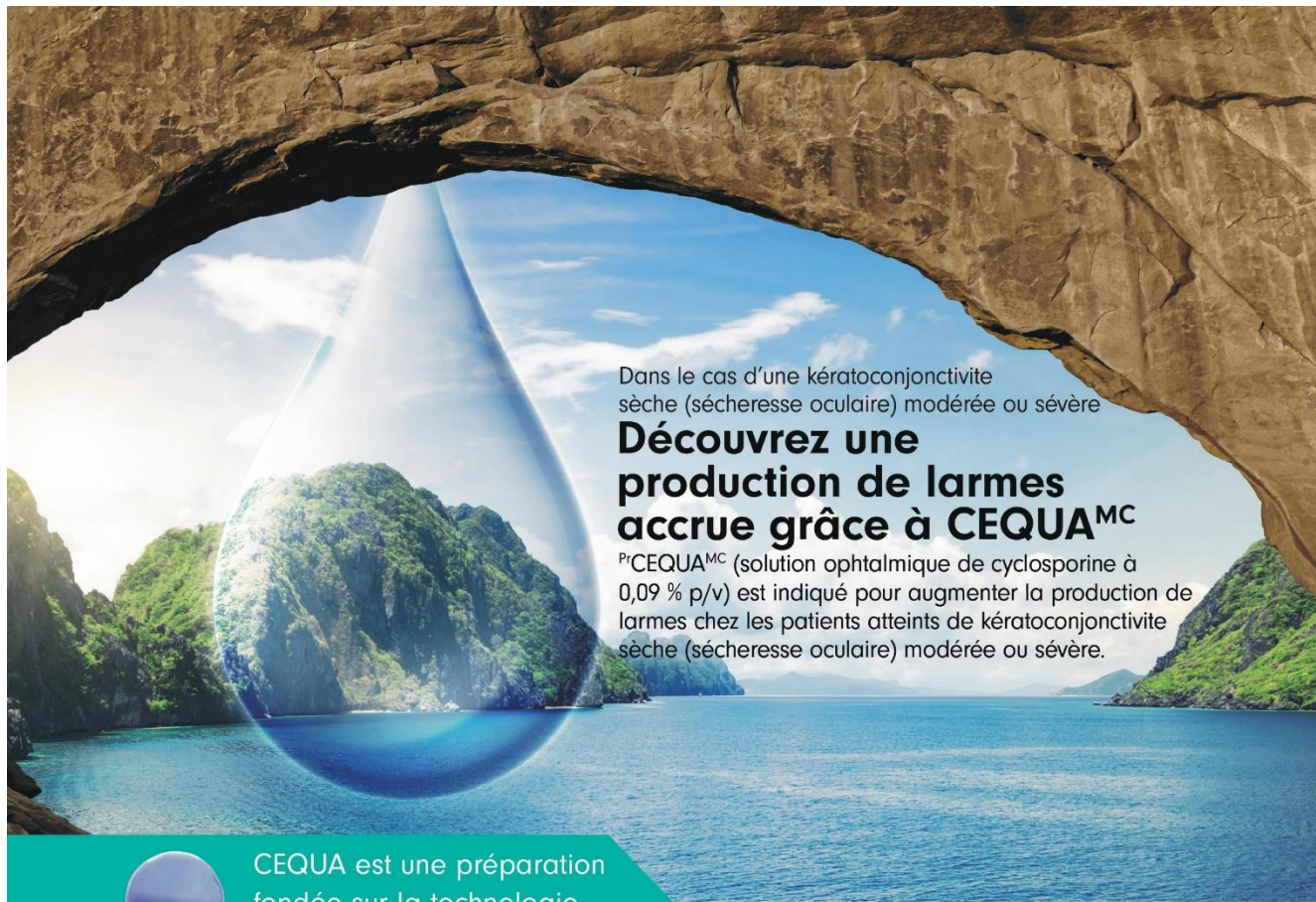
a condition that optometrists should recognize. Due to the difficulty of distinguishing the early signs and symptoms of OCP, as with this patient, it is often diagnosed at advanced stages. As a result, aggressive treatment is necessary. Unfortunately, many of these patients are elderly and could have difficulty handling the current forms of treatment. Due to the lack of well controlled clinical trials, a gold standard for treatment has not been developed. Treating OCP is challenging because the disease runs a different course in all patients and therapy has unpredictable outcomes. As a result, therapy generally consists of one or a combination of any of the following: oral corticosteroids, immunosuppressive therapy, TNF- $\alpha$  therapy, and/or intravenous immunoglobulin therapy. When determining therapy clinical experience, recent case reports, probable progression of the disease, and side effects are also considered. The most accepted method of treatment today consists of oral immunosuppressives with or without oral corticosteroids. When treating OCP it is also important to co-manage the disease with other health care providers such as dermatologists, primary care providers, and dentists due to the high likelihood of systemic involvement. It is important to realize that treatment does not reverse the damage already done, but reduces further progression, thus early detection is critical. Even with the development of new therapies recurrences are still possible; therefore frequent follow ups are important. □

## REFERENCES

1. Pflugfelder S, Beuerman R, Stern M, eds. Dry eye and ocular surface disorders. Care Marcel Dekker 2004.
2. Letko E, Miserocchi E, Daoud Y, et al. A nonrandomized comparison of the clinical outcome of ocular involvement in patients with mucous membrane (cicatricial) pemphigoid between conventional immunosuppressive and intravenous immunoglobulin therapies. *Clinical Immunology* 2004; 111: 303-310.
3. Chan L, Ahmed A, Anhalt G, et al. The first international consensus on mucous membrane pemphigoid. *Arch Dermatol* 2002; 138: 370-379.
4. Hingorani M, Lightman S. Ocular cicatricial pemphigoid. *Curr Opin Allergy Clin Immunol* 2006; 6: 373-378.
5. Pemphigus. Available at: [www.pemphigus.org](http://www.pemphigus.org). Last accessed 11/5/08.
6. Canizares M, Smith D, Connors M, et al. Successful treatment of mucous membrane pemphigoid with etanercept in 3 patients. *Arch Dermatol* 2006; 142: 1457-1461.
7. Ahmed M, Zein G, Khawaja F, et al., Ocular cicatricial pemphigoid: pathogenesis, diagnosis and treatment. *Prog Retin Eye Res* 2004; 23: 579-592.
8. Hoang-Xuan T, Robin H, Dermers Pierre E, et al. Pure ocular cicatricial pemphigoid. *Ophthalmology* 1999; 106: 355-361.
9. Friedman N, Kaiser P. The Massachusetts Eye and Ear Infirmary Illustrated Manual of Ophthalmology. Pennsylvania: Elsevier, Inc., 2004, p. 132-134.




10. Danier E, Thorne J. Recent advances in mucous membrane pemphigoid. *Curr Opin Ophthalmol* 2008; 19: 292-297.
11. Foster C. Cicatricial pemphigoid. *Trans Am Ophthalmol Soc* 1986; 84: 527-663.
12. Immunology. Available at: <http://www.microvet.arizona.edu/courses/MIC419/Tutorials/cytokines.html>. Last accessed April 4, 2009.
13. Elder M, Bernauer W, Leonard J, Dart J. Progression of disease in ocular cicatricial pemphigoid. *Br J Ophthalmol* 1996; 80: 292-296.
14. Miserocchi E, Baltatzi S, Manollette A, et al. The effect of treatment and its related side effects in patients with severe ocular cicatricial pemphigoid. *Ophthalmology* 2002; 109: 111-118.
15. Bruch-Gerharz D, Hertl M, Ruzicka T. Mucous membrane pemphigoid: clinical aspects, immunopathological features and therapy. *Eur J Dermatol* 2007; 17(3): 191-200.
16. Mondino B, Brown S. Ocular cicatricial pemphigoid. *Ophthalmology* 1981; 88: 95-100.
17. Mondino B, Brown S. Immunosuppressive therapy in ocular cicatricial pemphigoid. *Am J Ophthalmol* 1983; 96: 453-459.
18. Hardy K, Perry H, Pingree G, et al. Benign mucous membrane pemphigoid. *Archeology of Dermatology* 1971; 104: 467-475.
19. Neumann R, Rauber J, Foster C. Remission and recurrences after withdrawal of therapy for ocular cicatricial pemphigoid. *Ophthalmology* 1991; 98: 858-862.
20. Thorne J, Woreta F, Jabs D, et al. Treatment of ocular mucous membrane pemphigoid with immunosuppressive drug therapy. *Ophthalmology* 2008; 115: 2146-2152.
21. Vincent S, Lilly G, Baker K. Clinical, historic, and therapeutic features of cicatricial pemphigoid. *Oral Surg Oral Med Oral Pathol* 1993; 76: 453-459.
22. Nguyen Q, Foster C. Cicatricial pemphigoid: diagnosis and treatment. *Int Ophthalmol Clin* 1996; 36: 41-60.
23. Foster C, Wilson L, Ekins M. Immunosuppressive therapy for progressive ocular cicatricial pemphigoid. *Ophthalmology* 1982; 89: 340-353.
24. Kirtschig G, Murrell D, Wojnarowska F, et al. Interventions for mucous membrane pemphigoid/cicatricial pemphigoid and epidermolysis bullosa acquisita: a systematic literature review. *Arch Dermatology* 2002; 138: 380-384.
25. Thorne J, Anhalt G, Jabs D. Ocular mucous membrane pemphigoid. *Dermatol Ther* 2002; 15: 389-396.
26. Krueger G, Callis K. Potential of tumor necrosis factor inhibitors in psoriasis and psoriatic arthritis. *Arch Dermatol* 2004; 140: 218-225.
27. Lidington E, McCormack A, Yacoub M, et al. The effects of monocytes on the transendothelial migration of T lymphocytes. *Immunology* 1998; 94: 221-227.
28. Osborn L, Hession C, Tizard R, et al. Direct expression cloning of vascular cell adhesion molecule 1, a cytokine-induced endothelial protein that binds to lymphocytes. *Cell* 1989; 59: 1203-1211.
29. Henninger D, Panes J, Eppihimer M, et al. Cytokine-induced VCAM-1 and ICAM-1 expression in different organs of the mouse. *J Immunol* 1997; 158: 1825-1832.
30. Groves R, Allen M, Ross E, et al. Tumour necrosis factor-alpha is pro-inflammatory. *Br J Dermatol* 1995; 132: 345-352.
31. Munro J, Pober J, Cotran R. Tumor necrosis factor and interferon-gamma induce distinct patterns of endothelial activation and associated leukocyte accumulation in skin of *Papio Anubis*. *Am J Pathol* 1989; 135: 121-133.
32. Park W, Goodman R, Steinberg K, et al. Cytokine balance in the lungs of patients with acute respiratory distress syndrome. *Am J Respir Crit Care Med* 2001; 164: 1896-1903.
33. Tesar V, Jirsa M, Sima T, et al. Soluble cytokine receptors in renal vasculitis and lupus nephritis. *Med Sci Monit* 2002; 8: 24-29.
34. Menezes M, Benard G, Sato M, et al. In vitro inhibitory activity of tumor necrosis factor alpha and interleukin-2 of human immunoglobulin preparations. *Int Arch Allergy Immunol* 1997; 114: 323-328.



Dans le cas d'une kératoconjonctivite sèche (sécheresse oculaire) modérée ou sévère

## Découvrez une production de larmes accrue grâce à CEQUA<sup>MC</sup>

Pr<sup>CEQUA</sup><sup>MC</sup> (solution ophtalmique de cyclosporine à 0,09 % p/v) est indiqué pour augmenter la production de larmes chez les patients atteints de kératoconjonctivite sèche (sécheresse oculaire) modérée ou sévère.

 CEQUA est une préparation fondée sur la technologie des nanomicelles\*

\*La signification clinique n'est pas connue.

### Usage clinique :

**Enfants (< 18 ans) :** L'efficacité et l'innocuité de CEQUA n'ont pas été établies chez les enfants. Santé Canada n'a donc pas autorisé d'indication pour cette population.

**Personnes âgées (> 65 ans) :** Dans l'ensemble, aucune différence n'a été observée sur le plan de l'innocuité ou de l'efficacité entre les patients âgés et les patients adultes plus jeunes.

### Contre-indications :

- Patients qui présentent une hypersensibilité à ce médicament ou à l'un des composants du produit (y compris les ingrédients non médicinaux) ou du contenant
- Patients atteints d'infections oculaires ou périoculaires évolutives ou soupçonnées
- Patients atteints d'affections oculaires ou périoculaires malignes ou précancéreuses

### Mises en garde et précautions pertinentes :

- Destiné à un usage ophtalmique topique seulement
- Il convient de résoudre les infections oculaires ou périoculaires existantes ou soupçonnées

avant l'instauration d'un traitement par CEQUA. Si une infection se produit pendant le traitement, l'administration de CEQUA doit être interrompue jusqu'à ce que l'infection ait été enrayée.

- Il faut déconseiller aux patients de conduire un véhicule et d'utiliser des machines jusqu'à ce que leur vision soit redevenue normale après l'administration de CEQUA.
- CEQUA n'a pas été étudié chez des patients ayant des antécédents de kératite herpétique, de maladie des glandes lacrymales en phase terminale, de kératoconjonctivite sèche (KCS) causée par la destruction des cellules caliciformes conjonctivales comme dans le cas d'une carence en vitamine A, ou de tissu cicatriciel comme dans le cas d'une pemphigoïde cicatricielle, de brûlures causées par des produits alcalins, du syndrome de Stevens-Johnson, d'un trachome ou d'une exposition au rayonnement.
- Il faut surveiller de près les patients atteints d'une kératite grave.
- Risque de blessure et de contamination oculaires

- CEQUA ne doit pas être administré pendant que le patient porte des lentilles cornéennes.
- Infections et tumeurs locales : Une surveillance régulière est recommandée lorsque CEQUA est utilisé à long terme.
- Réactions d'hypersensibilité
- Les effets de CEQUA n'ont pas été étudiés chez des patients atteints d'insuffisance rénale ou hépatique.
- CEQUA est déconseillé pendant une grossesse, sauf si les avantages l'emportent sur les risques.
- Il faut faire preuve de prudence lors de l'administration de CEQUA aux femmes qui allaitent.

### Pour de plus amples renseignements :

Veillez consulter la monographie de CEQUA à l'adresse [https://pdf.hres.ca/dpd\\_pm/00060038.pdf](https://pdf.hres.ca/dpd_pm/00060038.pdf) pour des renseignements importants non abordés ici concernant les effets indésirables, les interactions médicamenteuses et la posologie. Vous pouvez aussi obtenir la monographie du produit en communiquant avec notre Service médical au numéro sans frais 1 844 924-0656.

**RÉFÉRENCE :** Monographie de CEQUA<sup>MC</sup> actuelle, Sun Pharma Global FZE.

## **Pour obtenir un crédit UFC pour ce cours**

Remplissez le questionnaire ci-dessous et renvoyez-le soit en ligne, par courriel ou par courrier ordinaire. Le coût de la notation de chaque quiz est de 25,00 \$ (plus taxes) et vous serez facturé via PayPal après avoir reçu votre certificat de crédit UFC. Ce cours expirera pour le crédit UFC le 31 mars 2024. Veuillez ne pas le soumettre après cette date.

**En ligne :** Accéder le questionnaire en ligne en cliquant ci-dessous à l'endroit indiqué. Complétez le test à l'écran, puis cliquez sur le bouton «SUBMIT» à la fin du quiz pour le soumettre à la notation. Si vous rencontrez un problème pour soumettre le test en ligne, soumettez le questionnaire par courriel ou par courrier ordinaire. Vous serez facturé via PayPal pour 25,00 \$ plus taxes après avoir reçu votre certificat de crédit UFC.

**Par courriel :** Accéder le questionnaire en ligne en cliquant ci-dessous à l'endroit indiqué. Inscrivez vos réponses au questionnaire de test (comme suit : 1-a. 2-c, 3-d... etc.) et incluez également votre nom, votre adresse postale et votre numéro de licence professionnelle, et envoyez-les a info@optomed.ca . Vous serez facturé via PayPal pour 25.00\$ plus taxes après avoir reçu votre certificat de crédit UFC.

**Par courrier ordinaire :** Accéder le questionnaire en ligne en cliquant ci-dessous à l'endroit indiqué. Inscrivez vos réponses au questionnaire de test (comme suit : 1-a. 2-c, 3-d... etc.) plus votre nom, votre adresse postale et votre numéro de licence professionnelle, et postez-les à Optomed Québec 421- 5885 Marc Chagall, Montreal QC H4W 0C1. Vous serez facturé via PayPal pour 25.00\$ plus taxes après avoir reçu votre certificat de crédit UFC.

<b>CLIQUEZ <u>&lt;ICI&gt;</u> POUR ACCÉDER AU QUESTIONNAIRE EN LIGNE</b>
--