

Ce cours a été approuvé par l'Ordre des Optométristes du Québec pour un (1) crédit UFC de catégorie A en santé oculaire, à la condition que le questionnaire à la fin de cet article soit complété et soumis en ligne ou par courrier au plus tard le 31 mars 2024. Il n'y a aucun coût pour accéder à cet article ou le télécharger, mais des frais de 25 \$ s'appliqueront pour noter le questionnaire et transmettre un certificat UFC personnalisé. Les détails du processus de soumission sont inclus dans le questionnaire.

## **Glaucomatocyclitic Crisis: A Case Report and Review**

*Rex B. Villegas, OD, FAAO*

### **ABSTRACT**

**Background:** Glaucomatocyclitic crisis is an ocular disease that is characterized by a minimal non-granulomatous anterior uveitis that coincides with a dramatic elevation in intraocular pressure. The disease is usually unilateral and typically affects young adults, with males affected more than females. It is treated with and responds well to topical steroidal and ocular hypotensive agents. **Case Report:** A healthy 26-year-old Asian male presented with minimal, intermittent pain in the left eye for three days. Ocular health examination revealed a minimal, non-granulomatous anterior uveitis and elevated intraocular pressure in the left eye. The patient was treated with topical steroidal, ocular hypotensive, and cycloplegic agents for the subsequent days following the initial visit with complete resolution of the iritis. No glaucomatous damage to the optic nerve was detected, and the patient is currently being managed as a glaucoma suspect. The case report includes a discussion on the diagnosis and management of glaucomatocyclitic crisis, the possible etiologies, and the various differential diagnoses. **Conclusion:** The exact cause of the disease is unknown, although it is widely speculated that it is associated with a herpes-related trabeculitis. Regardless of the etiology, treatment is aimed at controlling the inflammation and uveitis. Management includes careful monitoring of the patient as the disease is recurrent and patients have an increased risk of developing primary open-angle glaucoma.

### **INTRODUCTION**

Glaucomatocyclitic crisis, also known as Posner-Schlossman Syndrome, is an acute, minimal non-granulomatous anterior uveitis associated with a dramatic

elevation in intraocular pressure.<sup>1</sup> The disease is typically unilateral although bilateral cases have been reported. The disease typically affects young adult males, and its propensity for recurrence puts the patient at risk for developing optic nerve changes and, thus, open-angle glaucoma.<sup>2</sup> No etiology has been clearly defined, although there is support for an infective trigger from the herpes virus.<sup>2-4</sup> An autoimmune etiology has also been proposed as it has been associated with HLA-Bw54.<sup>5</sup>

A case report is presented that details the diagnosis and appropriate management of the condition.

### **CASE REPORT**

A 26-year-old Asian male presented to our office on a Monday morning (Day #1) for a walk-in emergency visit. His chief complaint was having minimal and intermittent pain in his left eye for three days. He described the pain as feeling mildly "bruising," although he reported that it was tolerable and not extremely painful. He reported having no other ocular complaints, including having no conjunctival discharge, redness, itchiness, or foreign body sensation. He reported having no visual complaints as well and that his vision seemed to be unaffected by the pain. Additionally, he said that he experienced no photophobia, photopsia, or floaters. This was the patient's first visit to our office, although he reported having a comprehensive eye exam one year prior. His ocular history was remarkable for prescription computer-only spectacles, which were prescribed the previous year. He reported to be in good medical health and was not taking any medications. At the time of the exam, he had no headaches, muscle weakness, or other physical symptoms. He had no recent ocular or head trauma. His last physical examination was eight months ago and he reported it to be unremarkable. He had no known drug allergies. His occupation was a computer programmer. He was alert to person, place, and time.

His entering uncorrected distance and near visual acuities were 6/6 (20/20) OD, OS, and OU. Uncorrected cover test at distance and near showed no movement. Pupillary responses were tested with a transilluminator. Pupils were equal, round, and reactive to light without an afferent defect. The patient reported minimal pain in the

---

R.B. Villegas — Private Practice, Burbank, CA

Correspondence to: Dr. Rex B. Villegas, 201 E. Angeleno Avenue, Unit 408, Burbank, California 91502; E-mail: rex.villegas@gmail.com

The author has no financial interest in any material mentioned in this article. This article has been peer-reviewed.

left eye when the transilluminator was placed in front of either eye. Extraocular motilities were smooth, accurate, full, extensive, and painless while pursuing a transilluminator. Confrontational fields were full to finger counting OD and OS. Blood pressure was 125/75 mmHg and resting pulse was 75 beats/minute. Objective refraction by retinoscopy was OD +0.50 DS and OS +0.50 DS. Subjective manifest refraction was OD +0.75 DS and OS +0.75 DS with visual acuities of 6/6 (20/20) OD, OS, and OU. Distance phoria through the subjective refraction showed no lateral or vertical phoria. Near visual acuities through the distance subjective refraction was 6/6 (20/20) OD, OS, and OU. Near phoria through the distance subjective refraction was 3<sup>Δ</sup> exophoria with no vertical phoria. Negative and positive relative accommodations at 40 cm were +2.50 and >-3.00, respectively.

Anterior segment slit lamp examination of both eyes showed clear eyelids and lashes, clear conjunctiva and sclera, flat and intact irises, and clear crystalline lenses. Nasal and temporal anterior chamber angles in both eyes were grade 4 open as measured by the Van Herrick technique. Examination of the cornea in the right eye was clear. Corneal examination in the left eye showed two discreet, fine, and white keratic precipitates on the infero-central mid-peripheral endothelium. There was no corneal edema in the left eye. The anterior chamber of the right eye was deep and quiet without signs of inflammation. The anterior chamber of the left eye was deep and had trace cells and no flare with the observation of a single cell when examined with a 2-mm conical slit lamp beam. Intraocular pressures (IOP) were measured by Goldmann applanation tonometry (GAT) and were 16 mmHg OD and 42 mmHg OS at 9:30 am. Gonioscopy showed anterior chamber angles that were open to the ciliary body band 360 degrees with 1+ pigment in the trabecular meshwork in both eyes. There was no evidence of angle closure or peripheral anterior synechiae in either eye.

The right eye was dilated in office with phenylephrine hydrochloride 2.5% and tropicamide 1.0%. In the left eye, one drop of prednisone acetate 1.0% (Pred Forte™, Allergan), one drop of timolol maleate 0.5%, and one drop of scopolamine 0.25% were instilled in office. Post-dilated IOPs were measured at 10:30 am and were 16 mmHg OD and 41 mmHg OS. There was no closure of the anterior chamber angles upon dilation of either eye. Dilated fundus examination showed cup:disc (C/D) of 0.4/0.4 (vertical/horizontal) OD and OS with deep cups and no damage to the neural rims. The optic nerves of both eyes were pink with distinct rims. Nerve fiber layers of both eyes were healthy with no apparent defects. There were no signs of retinal vascular hemorrhaging or inflammation in either eye. The retinal peripheries in both eyes were flat and intact. The vitreal chambers were clear with no signs of inflammation OU.

The patient was diagnosed with a minimal, non-granulomatous anterior uveitis with a concurrent marked elevation in IOP in the left eye. There was no evidence of acute, intermittent, chronic, partial, or complete angle closure. There was also no evidence of posterior uveitis or retinal vasculitis. These signs and the patient's minimal symptoms were consistent with glaucomatocyclitic crisis. The patient was prescribed Pred Forte q3h OS. He was instructed to return to the office later in the day at 5:00 pm for an IOP check and instillation of additional topical ocular hypotensive agents if necessary.

The patient returned in the afternoon and reported improvement in his symptoms. He said he was compliant with Pred Forte and that he instilled two drops since the morning office visit. He reported no pain in the left eye although he was mildly photophobic in the left eye. Anterior segment slit lamp examination of the right eye showed no changes from the earlier visit. Examination of the left eye showed a dilated left pupil and the presence of trace cells in the anterior chamber, which was unchanged from the previous examination in the morning. IOP measured by GAT was 16 mmHg OD and 25 mmHg OS at 5:30 pm. Dilated posterior segment examination of the left eye was unchanged from the morning examination.

At the conclusion of the exam, one drop of timolol maleate 0.5% and one drop of scopolamine 0.25% were instilled in the left eye. Based on the patient's improving symptoms and decreasing IOP, he was diagnosed with resolving glaucomatocyclitic crisis OS. The patient was educated about his condition, including the risk for the development of glaucoma and the potential for the condition to cause damage to his vision. Compliance with Pred Forte was stressed to control the inflammation. It was also stressed for him to return the next morning for an IOP check and instillation of additional ocular hypotensive and/or cycloplegic agents if necessary.

The patient returned the next morning (Day #2) and reported compliance with Pred Forte q3h OS throughout the previous evening. He said his left eye felt well with no pain or discomfort. Entering uncorrected visual acuities were 6/6 (20/20) OD, OS, and OU. Anterior segment slit lamp examination was unchanged in the right eye. The left eye showed a dilated pupil (secondary to the previous day instillation of scopolamine) with no cells or flare in the anterior chamber. There was a single KP on the corneal endothelium of the left eye. IOP measured by GAT were 16 mmHg OD and 16 mmHg OS at 9:30 am. Dilated fundus examination was unchanged from the previous visits OU. Because of the marked improvement in IOP and the resolved iritis in the left eye, the patient was instructed to decrease Pred Forte instillation to q.i.d. The patient returned to the office later that same day for an IOP check, which was 16 mmHg OD and 16 mmHg

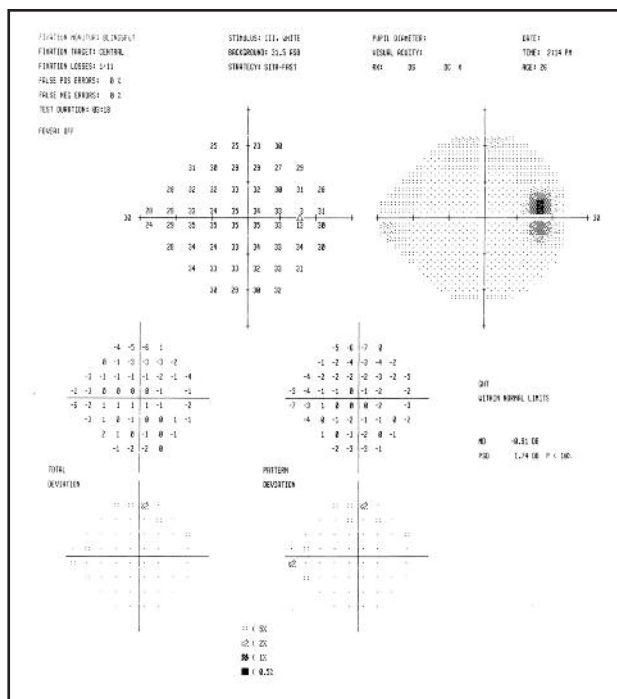


Fig. 1 Mean deviation for the right visual field measured -0.91 db

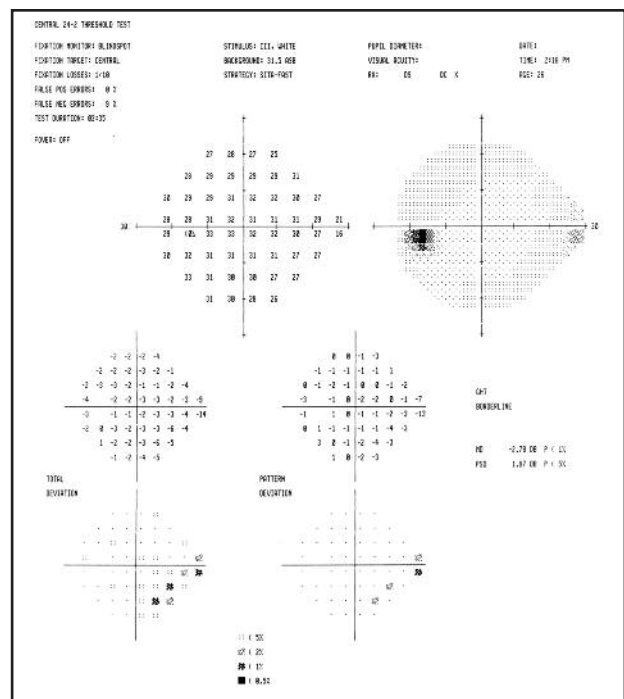


Fig. 2 Mean deviation for the left visual field measured -2.78 db

OS at 5:30 pm. At the conclusion of the exam (Day #2) he was instructed to continue Pred Forte q.i.d. OS for 2 days and then discontinue, and he was scheduled for daily IOP checks over the next several days, with alternating morning and afternoon appointments to rule out diurnal variation.

Ocular health examinations were unchanged over the next several visits. The IOPs over the subsequent visits were:

- Day #3: 15 mmHg OD and 16 mmHg OS at 10:00 am
- Day #4: 16 mmHg OD and 15 mmHg OS at 4:30 pm
- Day #5: 16 mmHg OD and 16 mmHg OS at 9:30 am
- Day #6: not checked
- Day #7: 16 mmHg OD and 16 mmHg OS at 3:30 pm
- On Day #7, a Humphrey visual field 24-2 SITA-Fast test was performed. The results for the right eye were reliable (1/11 fixation losses, no false positives, no false negatives) and showed no specific defects and patterns of depressions. The mean deviation for the right visual field measured -0.91 db (Fig. 1). The results for the left eye were reliable (1/10 fixation losses, no false positives, 9% false negative) and showed a minimal depression in the infero-nasal quadrant just below the horizontal midline. The mean deviation for the left visual field measured -2.78 db (Fig. 2). IOP measured 16 mmHg OD and OS at 3:30 pm. The anterior chamber angles were reevaluated by

gonioscopy and showed angles open to the ciliary body band and 1+ trabecular meshwork pigment 360 degrees in both eyes with no evidence of angle closure or peripheral anterior synechiae. Dilated fundus exams were unchanged from previous examinations and showed no apparent damage or cupping to the optic nerves in both eyes.

The patient was diagnosed with resolved glaucoma-tocyclitic crisis OS. However, the visual field findings in the left eye were anomalous. They were consistent with an early, inferior nasal step that could have resulted from elevated IOP. He was diagnosed as a glaucoma suspect secondary to the hypertensive episode and visual field changes. The patient was educated on the signs and symptoms of angle closure and uveitis and was told to return to the office should he experience any symptoms. He was also educated on glaucoma and the relationship between elevated IOP and visual field changes. The importance of periodic IOP checks and visual field tests were stressed. The patient opted to seek medical care with a provider within his HMO network. A letter was written for the patient to bring to the specialist in his network. In the letter, the patient's condition was explained in detail, and a copy of the visual fields was included that noted the inferior nasal area of the left eye field. It was recommended that threshold visual fields be repeated and

baseline retinal tomography, nerve fiber layer analysis, and optic nerve photos be taken. It was also recommended that if the visual fields were reliable and repeatable that the patient begin medical treatment with aqueous suppressants (beta-blockers or -adrenergic agonists) to prevent fluctuations in IOP. To rule out an underlying cause for the iridocyclitic attack, a baseline medical work-up was recommended, including complete blood count, erythrocyte sedimentation rate, Venereal Disease Research Laboratory test, and fluorescent treponemal antibody absorption test.

A phone call from the patient's ophthalmologist was received two weeks after the patient's last visit. He received the letter that was sent and agreed with the diagnosis of glaucomatocyclitic crisis, noting the presence of a single keratic precipitate in the left eye. The ophthalmologist reported that Humphrey visual field 30-2 SITA-Std tests were performed and were reliable, full, and repeatable OD and OS. The area of depression OS in the initial 24-2 SITA-Fast test was not repeatable and was likely due to patient error (the patient's first time taking the test). The ophthalmologist reported consistent IOPs of 15 mmHg OD and OS and no signs of angle closure or uveitis. The patient was scheduled for follow-up every 6 months for IOP checks and visual field tests. The patient has been co-managed over the past 3 years and has not had any recurrent attacks.

## DISCUSSION

Glaucomatocyclitic crisis is a syndrome that was first described by Adolph Posner and Abraham Schlossman in 1948. They described seven general characteristics of the syndrome:

- The disease is unilateral.
- The presenting symptom is usually slight discomfort or visual blur, although the patient may also be asymptomatic.
- The eye appears generally white and quiet, although mild corneal edema may develop as a result of ocular hypertension.
- Ocular hypertension coincides with a mild anterior uveitis, indicated by trace cells, flare, and keratic precipitates.
- The anterior chamber angle is open with no angle closure or peripheral anterior synechiae.
- The ocular hypertension can last from a few hours to one month, but rarely over two weeks.
- Episodes of attacks may occur without apparent cause and vary in frequency from many attacks in a short period of time to few attacks over a long period of time.<sup>1</sup>

Glaucomatocyclitic crisis, also called Posner-Schlossman syndrome (PSS), typically affects young adults, with males affected more frequently than females.

Attacks are initially unilateral, although 50% of patients develop bilateral attacks at different times.<sup>2</sup> The hallmark of the condition is a dramatic elevation in intraocular pressure (IOP) (usually between 40-60 mmHg) associated with a disproportionately minimal non-granulomatous anterior uveitis.<sup>1,6-9</sup> The high IOP can cause a mild corneal edema. During the active phase of the condition, very few cells are seen in the anterior chamber and very few keratic precipitates are seen on the inferior corneal endothelium. The disease responds well to medical therapy<sup>10,11</sup> with complete resolution of attacks, although patients should be followed closely over time as the condition can recur and these patients have an increased risk of developing primary open-angle glaucoma (POAG).<sup>2,12</sup>

The exact pathogenesis of the disease is not known, although several etiologies have been postulated in the past. In 1935, Kraupa described patients with uniocular inflammation and glaucoma, and emphasized that his patients were "neurasthenic, angiopathic, heavy cigarette smokers, and one had [spastic intestinal disturbance]."<sup>13</sup> Posner and Schlossman suggested an abnormality of the hypothalamus and autonomic nervous system due to their observation of PSS in patients with hypertensive vascular disease, migraine, anisocoria, and iris heterochromia.<sup>1</sup> In 1949, Givner described a patient with episodes of cyclitic uniocular glaucoma that were inexplicably associated with afternoon fever, fatigue, and diarrhea.<sup>13</sup> Israel, Rouher, and Levatin described cases that were coincident with dental anomalies in 1952, 1955, and 1956, respectively. In 1957, Burton described a patient whose 15 episodes of the disease were preceded by exposure to cold temperatures.<sup>13</sup> More recently, Hirose et al found a relationship between PSS and HLA-Bw54, suggesting that PSS is an autoimmune condition.<sup>5</sup>

While no etiology has been confirmed, it is widely speculated that PSS is caused by an acute inflammation of the trabecular meshwork that impedes aqueous humor outflow.<sup>2,4,7</sup> Furthermore, the exact cause of this trabeculitis has not been determined, although there is support for an infective trigger. In a study of three patients with active attacks of PSS, Yamamoto et al found that all three patients had evidence of the herpes simplex virus (HSV) in the aqueous humor when the humor was examined by polymerase chain reaction (PCR) amplification. Because HSV commonly infects cranial nerve V (and can remain latent in the trigeminal ganglion), and considering that the trabecular meshwork is innervated by the ophthalmic division of the trigeminal nerve, it is suggestive that HSV is the cause of the trabeculitis in PSS.<sup>3</sup> Support for an HSV-related cause for PSS is strengthened by the fact that HSV is known to cause herpetic kerato-uveitis.<sup>3</sup> In 2005, Teoh et al described a case of a recurring, and eventually recalcitrant, case of bilateral PSS. When the aqueous



humor of this patient was examined by PCR amplification, the results were strongly positive for the presence of cytomegalovirus.<sup>4</sup> This was consistent with a study by Bloch-Michel et al, who found the presence of antibodies to cytomegalovirus in patients with active PSS.<sup>4</sup> The findings of both HSV and cytomegalovirus in the aqueous humor of active PSS may indicate that PSS is an inflammatory response to infections from the Herpesviridae family.<sup>4</sup>

The most prominent clinical characteristic of PSS is its dramatic elevation in IOP, which usually ranges between 40-60mm Hg during attacks. IOP in this range puts the eye at risk for developing optic nerve damage due to acute glaucoma. Park et al studied optic nerve topography using confocal scanning laser tomography in a group of six patients with recurring PSS.

Measurements of disc area, cup area, cup/disc ratio, rim area, cup volume, rim volume, and cup depth were taken during PSS attacks and after remission (average time interval after remission was 38.5 days). When IOP was reduced in PSS attacks, they found a corresponding decrease in optic nerve cup volume and increase in rim area and rim volume.<sup>14</sup> Darchuk et al conducted a similar study. They analyzed the dynamics of optic nerve head blood flow by retinal confocal tomography and Scanning Laser Doppler Flowmetry. Optic nerve rim volume, rim area, cup volume, and cup area were analyzed before, during, and after PSS attacks. In a group of four patients, it was shown that PSS produced a decrease in rim volume and rim area and an increase in cup volume and cup area during ocular hypertensive attacks. However, the changes were transient, harmless, and reversed when the attacks subsided.<sup>15</sup> Additionally, they found that there was no visual field damage due to the hypertensive episodes. It is not certain what the mechanism is that causes optic nerve topographical changes, but there is support that the changes may be due to an IOP-related anterior repositioning of a posteriorly-displaced lamina cribrosa.<sup>14</sup>

The relationship between PSS and the primary open-angle glaucoma (POAG) has been studied. Kass et al studied a group of 11 patients with diagnosed attacks of PSS over a 13 year period. Five of the 11 were later diagnosed with bilateral POAG secondary to glaucomatous visual field defects. Interestingly, four of the patients also had a positive glucose tolerance test or overt diabetes.<sup>12</sup> Considering the high prevalence of diabetes mellitus in patients with POAG, the authors suggested that a relationship is possible between diabetes, POAG, and PSS. Furthermore, they suggested that all patients with PSS should undergo a glucose tolerance test.<sup>12</sup> In a retrospective study of 53 patients with PSS, Jap et al found that 26.4% developed glaucomatous damage (visual field loss and/or optic nerve cupping) due to repeated attacks. The risk for developing glaucoma was

proportional to the length of time of having the syndrome. Patients with the disease for longer than 10 years had a 2.8 times higher risk for developing glaucoma. They recommended that all patients with PSS be carefully examined for evidence of glaucoma even in the absence of POAG.<sup>8</sup>

Ocular hypertension in PSS generally will subside in a few weeks if left untreated, but the risk of long-term optic nerve or visual field damage warrants immediate treatment.<sup>10</sup> The ocular hypertension is highly responsive to aqueous suppressive medical therapy. Muthusamy described two cases of PSS in which the IOPs were treated with apraclonidine 1%. Both showed a drop in IOP within one hour of application of the drops.<sup>11</sup> When treating PSS, IOP-lowering medications such as beta-blockers and -adrenergic agonists should be used.<sup>7</sup> Hong and Song suggested that apraclonidine may be the medication of choice due to the possible mechanism of prostaglandin-mediated hypotensive effects.<sup>16</sup> Miotics are ineffective and are contraindicated.<sup>16</sup> The clinician should be wary about using prostaglandin-analogues such as latanaprost 0.005% due to paradoxical IOP-increasing effects. While prostaglandin-analogues generally decrease IOP, they may increase the blood-aqueous barrier permeability and increase the IOP in this particular syndrome.<sup>7</sup> Topical corticosteroids are effective for treating the mild iritis<sup>10,17</sup> and topical cycloplegics are effective for alleviating mild pain.<sup>17</sup> There is also support for surgical intervention for the treatment of recurrent attacks of PSS. In their study of 53 patients with PSS, Jap et al described nine eyes that underwent glaucoma filtering surgery. 80% of them were successful in preventing IOP spikes during cyclitic attacks. Furthermore, the severity of the cyclitic attacks was reduced, suggesting that improvement of aqueous outflow may contribute to egression of inflammatory mediators.<sup>8</sup> This theory was also supported by a case presented by Dinakaran and Kayarkar. They described a case of recurrent, bilateral PSS that was treated with trabeculectomy. The patient had no IOP spikes or recurrent uveitis in the subsequent 4-year follow-up.<sup>18</sup>

PSS is a unique condition in that it is inflammatory but causes hypertensive effects. Normally, ocular inflammation results in a decreased IOP secondary to inflammatory damage to the ciliary body, thus lowering the production of aqueous humor.<sup>7</sup> However, IOP elevation may occur due to inflammatory damage to the trabecular meshwork, clogging of the trabecular meshwork with inflammatory debris, or an increase in aqueous viscosity due to the presence of inflammatory byproducts.<sup>7</sup> However, these conditions usually occur in chronic inflammation, whereas PSS is an acute condition. The differential diagnoses for PSS should include conditions that cause dramatic changes in IOP as well as glaucoma secondary to inflammation.

Angle closure causes a unilateral increase in IOP as well as corneal edema in the involved eye. The patient will have acute pain, blurred vision, frontal headache, and nausea. The anterior chambers of both eyes will be shallow. The pupil in the involved eye will be fixed and dilated.<sup>19</sup>

Pigment dispersion syndrome can cause erratic variations in IOP, resulting in pigmentary glaucoma. IOP spikes can be acute and the patient will be asymptomatic or mildly symptomatic to blurred vision or eye pain. The typical patient profile is a young adult, myopic male.

Critical signs of this condition are the presence of iris pigment on the inferior corneal endothelium (Krukenberg's spindle) and heavy pigment deposition in the trabecular meshwork when viewed gonioscopically.<sup>19</sup>

Various uveitic conditions can cause an increase in IOP. Fuch's heterochromic iridocyclitis is a chronic condition that produces a unilateral low-grade anterior uveitis and increased IOP that does not resolve with treatment of the inflammation alone. Therefore, treatment should be aimed at lowering IOP and not managing the inflammation.<sup>20</sup> Critical signs of this condition include the presence of non-granulomatous keratic precipitates and diffuse iris atrophy (which may appear as a hypopigmented iris) without synechiae.<sup>20</sup> Herpes simplex virus can cause uveitic glaucoma. These patients may show keratic precipitates underlying areas of dendritic keratitis.<sup>20</sup>

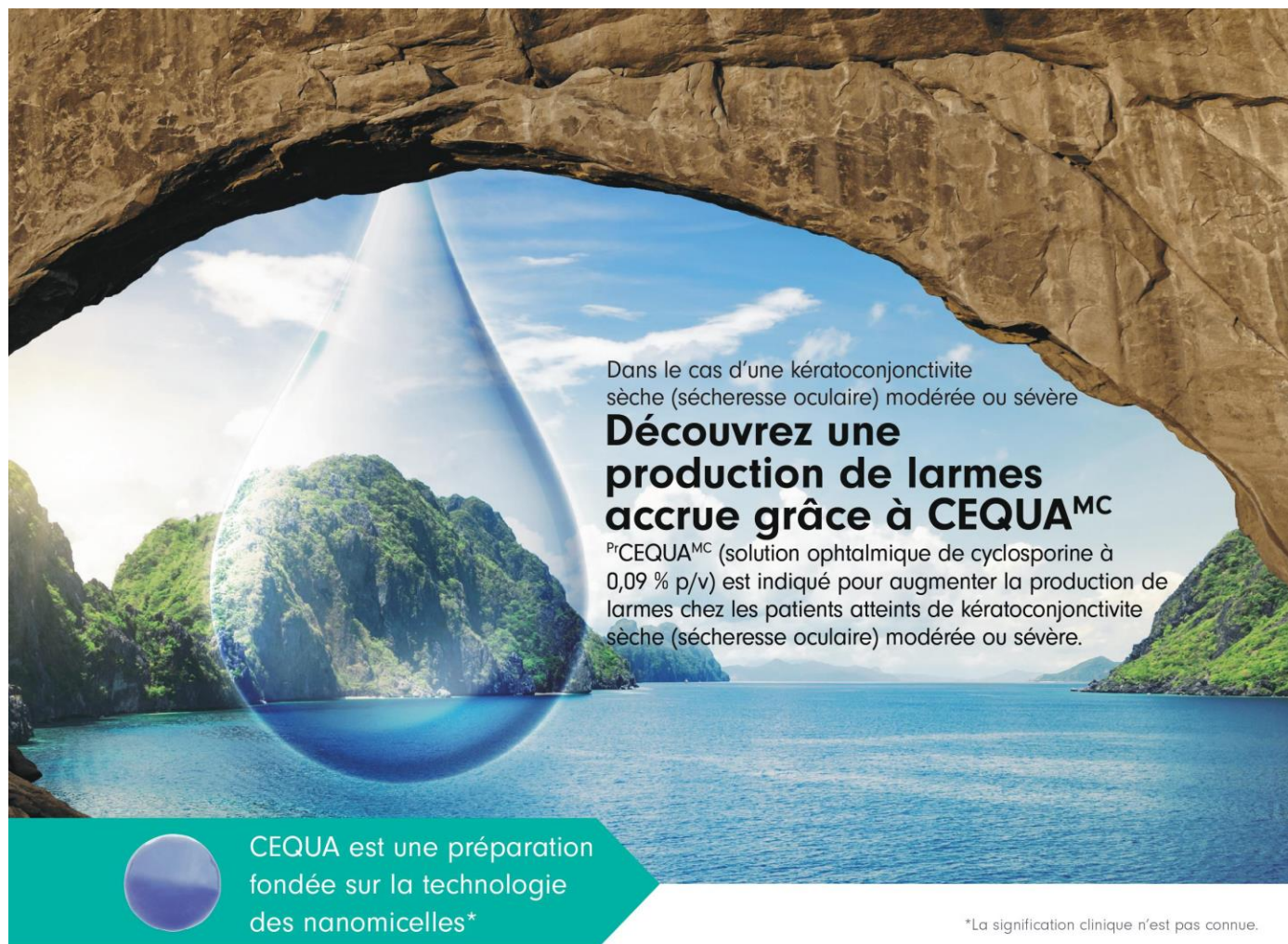
## CONCLUSION

The case presented illustrates that glaucomatocyclitic crisis is a diagnosis that can be made clinically. The clinician must be keen on the patient's minimal symptoms and thorough upon ocular health examination to detect the minimal signs it presents with. There are several differential diagnoses, although careful examination should accurately diagnose PSS. Patients with PSS should be monitored closely over their life for recurring attacks and the development of open-angle glaucoma. While surgical intervention has been shown to prevent IOP spikes and reduce cyclitic episodes, the best management of this condition is medical therapy as necessary to treat attacks and control the development of glaucoma. Additionally, the clinician must be mindful of the peculiar relationship between the herpes virus and PSS. O

## REFERENCES

1. Posner A, Schlossman A. Syndrome of unilateral recurrent attacks of glaucoma with cyclitic symptoms. *Arch Ophthalmol* 1948; 39: 517-35.
2. Kanski JJ. *Clinical Ophthalmology*. 6th Ed. Edinburgh: Butterworth-Heinemann 2007.
3. Yamamoto S, Tada R, Yamamoto R, et al. Possible role of herpes simplex virus in the origin of Posner-Schlossman syndrome. *Am J Ophthalmol* 1995; 199: 796-798.
4. Teoh S, Thean L, Koay E. Cytomegalovirus in aetiology of Posner-Schlossman syndrome: evidence from quantitative polymerase chain reaction. *Eye* 2005; 19(12): 1338-1340.
5. Hirose S, Ohno S, Matsuda H. HLA-Bw54 and glaucomatocyclitic crisis. *Arch Ophthalmol* 1985; 103: 1837-1839.
6. DeRoeth A. Glaucomatocyclitic crisis. *Am J Ophthalmol* 1970; 69: 370-371.
7. Harrington J. Posner-Schlossman syndrome: a case report. *J Am Optom Assoc* 1999; 70: 715-723.
8. Jap A, Sivakumar M, Med M, Chee S. Is Posner Schlossman syndrome benign? *Ophthalmology* 2001; 108: 913-918.
9. Green R. Posner-Schlossman syndrome (glaucomatocyclitic crisis). *Clin Exp Optom* 2007; 90: 53-56.
10. Hung P, Chang J. Treatment of glaucomatocyclitic crises. *Am J Ophthalmol* 1974; 77: 169-172.
11. Muthusamy P. Apraclonidine in the management of glaucomatocyclitic crisis. *Eye* 1994; 8: 367-368.
12. Kass M, Becker B, Kolker A. Glaucomatocyclitic crisis and primary open-angle glaucoma. *Am J Ophthalmol* 1973; 75: 668-673.
13. Knox D. Glaucomatocyclitic crises and systemic disease: peptic ulcer, other gastrointestinal disorders, allergy, and stress. *Trans Am Ophthalmol Soc* 1988; 86: 473-495.
14. Park K, Hong C. Reversal of optic disc topography in patients with glaucomatocyclitic crisis after remission of attack. *J Glaucoma* 1998; 7: 225-229.
15. Darchuk V, Sampaulesi O, Lopez Mato O, et al. Optic nerve head behavior in Posner-Schlossman syndrome. *Int Ophthalmol* 2001; 23: 373-379.
16. Hong C, Song K. Effect of apraclonidine hydrochloride on the attack of Posner-Schlossman syndrome. *Korean J Ophthalmol* 1993; 7: 28-33.
17. Malinovsky V. Glaucomatocyclitic crisis. *J Am Optom Assoc* 1983; 54: 1069-1070.
18. Dinakaran S, Kayarkar V. Trabeculectomy in the management of Posner-Schlossman syndrome. *Ophthalmic Surg Lasers* 2002; 33: 321-322.
19. Rhee D, Pyfer M. *The Wills Eye Manual*. Third Edition. Philadelphia: Lippincott, 1999.
20. Kaiser P, Friedman N, Pineda R II. *The Massachusetts Eye and Ear Infirmary Illustrated Manual of Ophthalmology* 2nd Ed. Philadelphia: Saunders 2004.






Dans le cas d'une kératoconjonctivite sèche (sécheresse oculaire) modérée ou sévère

## Découvrez une production de larmes accrue grâce à CEQUA<sup>MC</sup>

P<sup>r</sup>CEQUA<sup>MC</sup> (solution ophtalmique de cyclosporine à 0,09 % p/v) est indiqué pour augmenter la production de larmes chez les patients atteints de kératoconjonctivite sèche (sécheresse oculaire) modérée ou sévère.

 CEQUA est une préparation fondée sur la technologie des nanomicelles\*

\*La signification clinique n'est pas connue.

### Usage clinique :

**Enfants (< 18 ans) :** L'efficacité et l'innocuité de CEQUA n'ont pas été établies chez les enfants. Santé Canada n'a donc pas autorisé d'indication pour cette population.

**Personnes âgées (> 65 ans) :** Dans l'ensemble, aucune différence n'a été observée sur le plan de l'innocuité ou de l'efficacité entre les patients âgés et les patients adultes plus jeunes.

### Contre-indications :

- Patients qui présentent une hypersensibilité à ce médicament ou à l'un des composants du produit (y compris les ingrédients non médicinaux) ou du contenant
- Patients atteints d'infections oculaires ou périoculaires évolutives ou soupçonnées
- Patients atteints d'affections oculaires ou périoculaires malignes ou précancéreuses

### Mises en garde et précautions pertinentes :

- Destiné à un usage ophtalmique topique seulement
- Il convient de résoudre les infections oculaires ou périoculaires existantes ou soupçonnées

avant l'instauration d'un traitement par CEQUA. Si une infection se produit pendant le traitement, l'administration de CEQUA doit être interrompue jusqu'à ce que l'infection ait été enrayée.

- Il faut déconseiller aux patients de conduire un véhicule et d'utiliser des machines jusqu'à ce que leur vision soit redevenue normale après l'administration de CEQUA.
- CEQUA n'a pas été étudié chez des patients ayant des antécédents de kératite herpétique, de maladie des glandes lacrymales en phase terminale, de kératoconjonctivite sèche (KCS) causée par la destruction des cellules calciformes conjonctivales comme dans le cas d'une carence en vitamine A, ou de tissu cicatriciel comme dans le cas d'une pemphigoïde cicatricielle, de brûlures causées par des produits alcalins, du syndrome de Stevens-Johnson, d'un trachome ou d'une exposition au rayonnement.
- Il faut surveiller de près les patients atteints d'une kératite grave.
- Risque de blessure et de contamination oculaires

- CEQUA ne doit pas être administré pendant que le patient porte des lentilles cornéennes.
- Infections et tumeurs locales : Une surveillance régulière est recommandée lorsque CEQUA est utilisé à long terme.
- Réactions d'hypersensibilité
- Les effets de CEQUA n'ont pas été étudiés chez des patients atteints d'insuffisance rénale ou hépatique.
- CEQUA est déconseillé pendant une grossesse, sauf si les avantages l'emportent sur les risques.
- Il faut faire preuve de prudence lors de l'administration de CEQUA aux femmes qui allaitent.

### Pour de plus amples renseignements :

Veillez consulter la monographie de CEQUA à l'adresse [https://pdf.hres.ca/dpd\\_pm/00060038.PDF](https://pdf.hres.ca/dpd_pm/00060038.PDF) pour des renseignements importants non abordés ici concernant les effets indésirables, les interactions médicamenteuses et la posologie. Vous pouvez aussi obtenir la monographie du produit en communiquant avec notre Service médical au numéro sans frais 1 844 924-0656.

**RÉFÉRENCE :** Monographie de CEQUA<sup>MC</sup> actuelle, Sun Pharma Global FZE.

## INSTRUCTIONS POUR OBTENIR UN CREDIT UFC

Pour obtenir un crédit UFC pour ce cours remplissez le questionnaire ci-dessous et renvoyez-le soit en ligne, par courriel ou par courrier ordinaire. Le coût de la notation de chaque quiz est de 25,00 \$ (plus taxes) et vous serez facturé via PayPal après avoir reçu votre certificat de crédit UFC. Ce cours expirera pour le crédit UFC le 31 mars 2024. Veuillez ne pas le soumettre après cette date.

**En ligne :** Accéder le questionnaire en ligne en cliquant ci-dessous à l'endroit indiqué. Complétez le test à l'écran, puis cliquez sur le bouton «SUBMIT» à la fin du quiz pour le soumettre à la notation. Si vous rencontrez un problème pour soumettre le test en ligne, soumettez le questionnaire par courriel ou par courrier ordinaire. Vous serez facturé via PayPal pour 25,00 \$ plus taxes après avoir reçu votre certificat de crédit UFC.

**CLIQUEZ <ICI> POUR ACCÉDER AU QUESTIONNAIRE EN LIGNE**

**Par courriel :** Inscrivez vos réponses au questionnaire de test (comme suit : 1-a, 2-c, 3-d... etc.) et incluez également votre nom, votre adresse postale et votre numéro de licence professionnelle, et envoyez-les à [info@optomed.ca](mailto:info@optomed.ca) . Vous serez facturé via PayPal pour 25.00\$ plus taxes après avoir reçu votre certificat de crédit UFC.

**Par courrier ordinaire:** Inscrivez vos réponses au questionnaire de test (comme suit : 1-a, 2-c, 3-d... etc.) plus votre nom, votre adresse postale et votre numéro de licence professionnelle, et postez-les à Optomed Québec 421-5885 Marc Chagall, Montreal QC H4W 0C1. Vous serez facturé via PayPal pour 25.00\$ plus taxes après avoir reçu votre certificat de crédit UFC.