

# Article de crédit UFC

Ce cours a été approuvé par l'Ordre des Optométristes du Québec pour un (1) crédit UFC de catégorie A en santé oculaire, à la condition que le questionnaire à la fin de cet article soit complété et soumis en ligne ou par courrier au plus tard le 31 mars 2024. Il n'y a aucun coût pour accéder à cet article ou le télécharger, mais des frais de 25 \$ s'appliqueront pour noter le questionnaire et transmettre un certificat UFC personnalisé. Les détails du processus de soumission sont inclus dans le questionnaire.

## **Common Ocular Disorders in the Pediatric Population**

*David P. Sendrowski, OD, FAAO; Robert W. Lingua, MD*

### **ABSTRACT**

While most young children and infants are referred to the eye care physician with isolated ophthalmic problems for assessment and possible treatment, a smaller percentage will harbor serious ocular pathology which may be associated with co-existing systemic or neurologic abnormalities. Infant and early childhood development can be profoundly influenced by disorders of the visual system. The eye care physician should be aware of these common ocular pathologies for potential treatment options and urgency of referral if required by the condition.

The attention span of both infants and young children is quite limited and the eye care physician must conduct an accurate examination for these ocular disorders in a relatively brief period of time. Special exam techniques which are of particular importance and use in the diagnosis and management of these ocular disorders are discussed in this article.

### **INTRODUCTION**

Primary eye care physicians address ocular disease disorders in the adult population on a routine basis in their offices. Far less commonly, the pediatric ocular disease presents and may give concern of an ocular disorder which may be a harbinger of a more serious condition and that should not be missed on examination. Subjective tests routinely utilized in the adult exam may be difficult to perform or unreliable in pediatric patients. Additionally, a

child's ability to maintain concentration for only brief periods of time compounds the difficulty of making an accurate diagnosis.

The collaborative article you are about to read reviews common ocular disorders that the eye care physician may encounter within the pediatric population. Common pitfalls the practitioner may face and the decision-making process one might utilize with this particular patient population will also be discussed.

### **INFECTIONS OF THE EYE AND ANTERIOR ADENEXA**

Red eye is by far one of the more common reasons for the first encounter between a pediatric patient and an eye care physician.

Conjunctivitis is a very common ocular disease in this patient population. The Weiss Study from 1993 was an excellent overview of pediatric conjunctivitis.<sup>1</sup> Although some pathogens have changed, for the most part 80% of conjunctivitis in the pediatric population is bacterial while only 13% was shown to be of viral origin. The remaining etiologies were allergic and chemical in nature. Practitioners should examine the lower cul-de-sac for signs of injection, as well as the presence or absence of discharge, and/or foreign bodies. Bacterial infections produce a yellowish-green discharge while viral infections produce a more watery type. Both types of infections (viral and bacterial) can cause lid swelling and the lids to be glued shut upon awakening. Adenoviral infections can also be accompanied by a tender swelling of the lymph nodes in front of the ear (pre-auricular adenopathy). Cat-scratch fever (leptospirosis) following singular or multiple infected cat claw injuries can be a common cause of ocular glandular syndrome in young children.<sup>2</sup> Examination of the back of the hands and arms for the development of pustules near the site of a cat scratch can be extremely diagnostic.<sup>3</sup>

Bacterial pathogens most commonly encountered today are streptococcal, staphylococcal, and moraxella in species types.<sup>4</sup> Therefore, the physician must keep the treatment geared toward gram positive coverage when choosing a topical medication. Viral infections more commonly fall into the adenoviral variety which may be associated with a concurrent or antecedent upper

---

D.P. Sendrowski — Full Professor/Chief of Service, Ophthalmology Consultation/Chronic Care Service, Marshall B. Ketchum University, Southern California College of Optometry, Fullerton, CA; R.W. Lingua — Clinical Professor in Ophthalmology, Gavin Herbert Eye Institute, University of California, Irvine, CA

Correspondence to: Dr. David P. Sendrowski, Marshall B. Ketchum University, Southern California College of Optometry, 2575 Yorba Linda Boulevard, Fullerton, CA 92831-1699; E-mail: dsendrowski@ketchum.edu

The authors have no financial or proprietary interest in any of the material mentioned in this article.

This article has been peer reviewed.

respiratory infection.<sup>5</sup> Examination may reveal an inferior palpebral follicular reaction which is consistent with the viral pathogen. Fluorescein staining is an essential part of any conjunctivitis workup, especially in those considered viral, to rule out active Herpes virus keratopathy. If suspicion is high, start the patient on an oral acyclovir suspension, and refer for further testing.

A majority of bacterial infections respond extremely well to topical fourth generation fluoroquinolones which have the added advantage of less frequent administration and shorter duration of use (i.e., moxifloxacin, azasite, gatifloxacin). Older topical antibiotics can still be used as there is a tendency toward low morbidity of conjunctivitis and many pathogens are still responsive to these older antibiotic preparations (i.e., Polysporin, erythromycin and polytrim). Insurance providers and uninsured patients may request a cheaper drug alternative.

Viral infections are usually self-resolving requiring the need for symptomatic relief rather than therapeutic intervention. Non-preserved artificial tears kept in a cool place and cool compresses are commonly utilized for this task. For the more symptomatic patient, topical non-steroidal anti-inflammatory medications (NSAIDs) can be applied sparingly, as excessive use has been reported to cause corneal melt. One caveat the physician should remember is that adenoviral infections easily transfer to other members of the family especially siblings. Hand washing, especially before and after eye drop administration, is recommended.<sup>5</sup> Caution should be given to the parent regarding the sharing of pillows, towels and items that may have the potential for eye contact with other family members. Reduction of community spread is accomplished by restricting the child from school, community, or family activities where spreading might occur.

Allergic agents are numerous but when encountered in the pediatric population, they are commonly seen in the spring and fall. Ocular tissues are less injected and inflamed as with bacterial and viral infections, and knuckle rubbing by the child is more commonly seen than in the adult, along with the complaint of itching. Conjunctival chemosis may also be more prominent in these cases. Treatment of allergic conjunctivitis is best achieved with the use of topical combination medications (i.e., Pataday, Lastacast and Bepreve) for ease of use and rapid reduction of ocular itch and conjunctival chemosis. When resistant to topical mast cell-antihistamine combinations, topical steroids may be required for symptomatic relief in advanced vernal conjunctivitis, and to avoid formation of shield ulcers.<sup>6</sup>

Phlectenular disease, which was relatively common when tuberculosis was prevalent, is uncommon in developed countries like the United States.<sup>7</sup> Children still bear the burden of the patient population that will develop

phlectenular disease from severe staphylococcus lid infections. The disease delineates itself as a unilateral conjunctival inflammation with an elevated nodule in the interpalpebral area of the conjunctiva or cornea. The nodule is very responsive to topical corticosteroid therapy and represents a classic type IV delay hypersensitivity (Gell-combs) reaction.<sup>7</sup>

Chemical conjunctivitis is commonly associated with a history of swimming pool use. Most often, the inferior half of the eye is red and injected while the upper half is spared. This is probably a result of pooling of the chlorine into the inferior cul-de-sac location. A common pitfall by the examiner is to disregard the cornea evaluation or staining which in some cases may reveal "corneal burn" if extensive chemical contact has occurred.

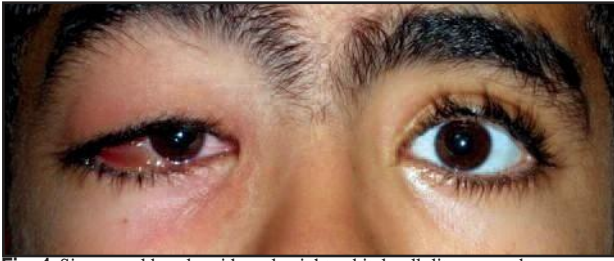Mild chemical damage to the cornea may be managed with a combination approach of topical cycloplegics, antibiotics and NSAIDs. Without corneal involvement, chemical conjunctivitis is best healed with irrigation via cool, non-preserved artificial tears kept in a cool location such as a pantry or refrigerator. In cases of punctate epithelial keratitis, topical ointment is preferred for the first 48 hours.

Finally, a group of conjunctivitis occurring after birth commonly referred to as "ophthalmia neonatorum" requires mentioning. The most common method of prophylaxis is instillation of erythromycin ointment at birth.<sup>8</sup> Pathogens that may encounter the eye during passage through the birth canal include neisseria gonorrhea, chlamydial trachomatis and herpes simplex virus.<sup>8</sup> These ocular infections arise within the first several days to months after birth, however, as in the case of chlamydia, may present later and if untreated, may lead to a serious chlamydial pneumonitis. They commonly appear in the sequence that is stated above with neisseria gonorrhea being the earliest to manifest,<sup>7</sup> but any suppurative conjunctivitis seen in the immediate post-natal period needs cultures, and referral is recommended for systemic involvement. All three pathogens should be tested for in a laboratory series. This should be requested by the eye care physician as part of the ocular work-up.

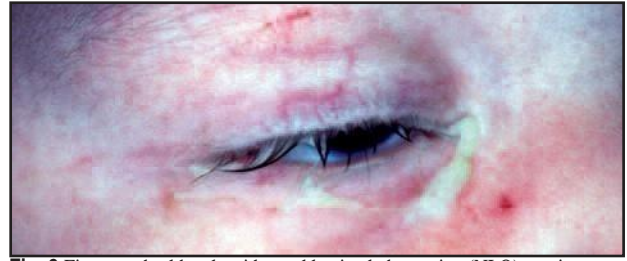## **PEDIATRIC LID INFECTIONS**

After conjunctivitis, lid infections are the second most common type of periocular infections found in children.

Acute hordeolum in children presents suddenly and is very elusive as to the causative pathogen.<sup>9</sup> Hordeolum usually increases rapidly over several days. Tender to palpation and localized inflammation in the lid gives the physician excellent physical clues to the etiology to a single infected sebaceous gland. Aggressive use of warm compresses and topical antibiotics (i.e., azithromycin) or antibiotic/steroid combination for reduction of inflammation is commonly utilized as the first therapeutic



**Fig. 1** Six-year-old male with early right orbital cellulites secondary to streptococcal infection of the upper respiratory system. Note early conjunctival edema and erythema.



**Fig. 2** Five-month-old male with nasal lacrimal obstruction (NLO) causing mucopurulent discharge from inferior puncta. Orbit and lids remain uninvolved from the blockage at this time.

management.<sup>9</sup> If the hordeolum fails to respond to hygiene and topical therapy, the patient can be started on systemic antibiotics with good soft tissue penetration (e.g., cephalexin). Due to the risk of progression to peri-orbital tissues or frank orbital cellulitis, failure to respond to oral agents within 48 hours requires prompt referral and the patient should be referred and set-up for incision and drainage of the lid lesion.

A more worrisome and often feared infection is orbital cellulites (Fig. 1). The preseptal type is localized to the ocular tissues anterior to the orbital septum.

Pediatric preseptal cellulitis is commonly associated with trauma to the lid tissues or a localized infectious/inflammatory disease (i.e., sinusitis), the latter to a greater degree. The physician's exams reveal a diffusely swollen and erythematous eyelid which is warm and tender to palpation. The child maintains good acuity and painless ocular motility. Pupils are normal to light response, and proptosis and fever are absent. One must always consider gram positive pathogens as the causative pathogen, making oral cephalosporins and fortified penicillins a first choice of therapeutic intervention by the practitioner. Infections that fail to respond to initial therapy require further laboratory and orbital image investigations, with modification to the therapeutic management being used to treat the infection (Fig. 1).

Viral pathogens are less common but may also affect the lid. Herpes Simplex presents with acute swelling, erythema and vesicle eruptions on the eyelids.<sup>10</sup> If the child is older they may report a tingling or tenderness to the affected lid area as well. Parent(s) should be queried about this symptom as well. Oral antivirals are commonly used as initial treatment. Once the clinical diagnosis is made, treatment should be initiated as soon as possible. The physician should always consider oral suspensions when treating pediatrics to make administration more tolerable for both patient and parent.

Finally, human papilloma virus in the form of Molluscum contagiosum (MC) can also frequent the lid of the pediatric patient.<sup>11</sup> These small, isolated umbilicated lesions are found along the periocular skin area. When

squeezed, a "cheesy" like substance manifests itself from the center of the lesion. If an MC occurs close to a lid margin, a follicular conjunctivitis can occur from dissemination of the molluscum bodies onto the ocular surface. Treatment of MC can be accomplished in several ways. The more common treatment options include: simple excision, incision and curettage, or cryosurgery. The patient is followed up every 2 to 4 weeks until the conjunctivitis resolves which often takes 4 to 6 weeks.<sup>11</sup>

#### NASOLACRIMAL DUCT OBSTRUCTION

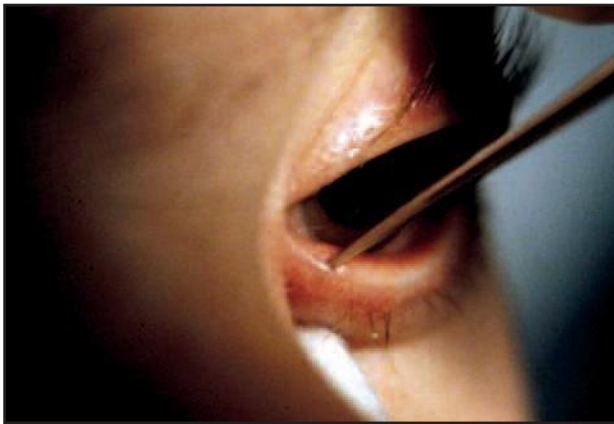Children with congenital obstruction of the nasolacrimal duct (NLD) will present within the first few months of life with what appears to be bacterial conjunctivitis with a copious mucoid discharge. Frequently, the eyelids are matted shut upon awakening in the AM. With pressure on the nasolacrimal sac, a yellow discharge can be produced in evidence of distal obstruction (Fig. 2). Spontaneous opening of the obstruction (i.e., valve of Hasner) in the first year of life is common, and treatment in the interim consists of measures to prevent peri-orbital cellulitis. Frequent lid hygiene and topical antibiotics twice a day are recommended. Because of the long course of treatment, any topical steroid preparation is to be avoided due to the reported association with secondary glaucoma.

Nasolacrimal duct obstruction may be partial, and the presenting complaint can be one of tearing whenever there is a condition that encourages evaporative ear loss, like fans, or when it is windy. If the obstruction does not clear spontaneously, surgical probing of the duct can be considered (Fig. 3); 1) urgently, in the presence of recurrent, severe peri-ocular cellulitis; or 2) electively, after one year of life, when the risks of anesthesia are less.

#### PEDIATRIC OCULAR TRAUMA

The most common mechanism of injury in the pediatric population is blunt trauma. In one study, it accounted for 65% of emergency room admittances.<sup>12</sup> Sporting activities were the more common cause of blunt trauma in the 5 to 14 year age group.<sup>12</sup>





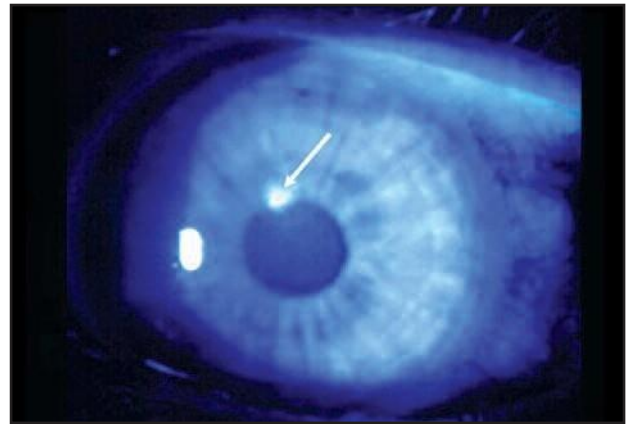
**Fig. 3** Inferior punctal dilation with lacrimal probe in a one-year-old infant. In the NLO patient, the procedure is done prior to opening the valve of Hasner with a Bowman probe.

In any history of trauma to the eye involving a fast moving object, penetration of the globe has to be presumed, until successfully ruled out, with a thorough dilated fundus exam. Innocent-appearing lacerations of the conjunctiva may be all that remain after penetration of the sclera with a sharp object. Corneal staining is first performed, followed by IOP determination and dilated indirect ophthalmoscopy. Imaging of the eye and orbit is suggested where penetration is suspected but unconfirmed by ocular exam. When there is evidence of globe penetration, the eye is shielded, followed by immediate referral to the ER.

#### **TRAUMATIC CORNEAL ABRASION**

Topical antibiotics, either as an ointment (erythromycin) or drops (fluoroquinolones) every 2-4 hours, are sufficient. Some doctors choose to patch, while others choose to place a bandage contact lens. In either case, it is necessary to check the cornea daily until re-epithelialization is complete. If the abrasion was due to a tree branch or other plant matter, concern exists for fungal contamination, and ciprofloxacin ointment every two hours is recommended.<sup>13</sup> If the pediatric patient requires a contact lens (post-surgical), anti-pseudomonal coverage is important, and again, ciprofloxacin ointment every two hours is needed. In the latter two cases, patching of the eye, creating an anaerobic environment, is discouraged. Oral suspension of ibuprofen can assist in pain control (Fig. 4).

Corneal foreign bodies with a deep rust ring may require removal with a burr. If the foreign body is located within the visual axis and involves the corneal stroma, post removal scarring may be a serious and visually threatening complication. A referral for deep debridement and antibiotic prophylaxis along with judicious steroids may be best option for these patients. Pediatric patients



**Fig. 4** Sodium fluorescein stain (pooling) of a corneal abrasion from an unknown foreign body in a three-year-old patient.

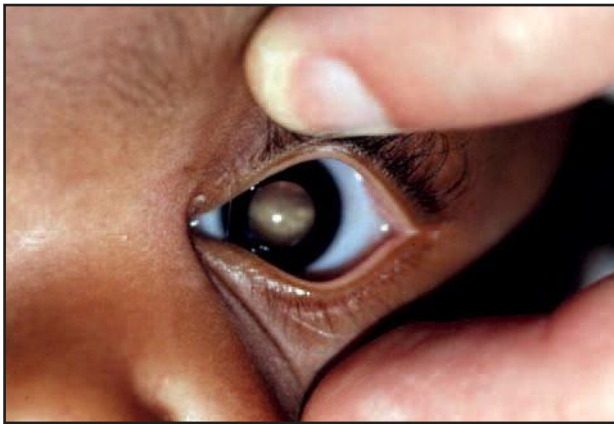will usually not tolerate procedures “in-office” and may require mild sedation in order to work on removing the foreign body without excessive eye or body movement.

#### **TRAUMATIC HYPHEMA**

If a complete (“eight ball”) eye presents, referral is suggested for hospitalization and consideration of surgical wash-out, and management of secondary iritis and glaucoma. In the case of minor anterior segment bleeding following trauma, much controversy still exists in regard to rest, patching and topical medications. The risk of an extensive, often greater re-bleed 3 to 4 days following trauma requires close monitoring in the office. It is difficult to differentiate floating blood cells from those due to anterior segment trauma and secondary iritis. Often in the presence of floating cells, treatment includes steroids empirically for 5 to 7 days. Atropine 1% daily is used to immobilize the pupil and discourage re-bleeding. Daily evaluation of IOP, anterior chamber reaction and blood level in the anterior chamber are required to prevent a vision threatening complication of hyphema in the first week of care. Once past the re-bleed risk period of five days, treatment continues on a less frequent basis until the chamber is clear and the pressure is normal. Angle recession glaucoma can follow blunt trauma and therefore gonioscopy and IOP check are recommended three months post injury.<sup>14</sup>

#### **TRAUMATIC IRITIS**

Blunt injury to the eye or orbit may result in signs and symptoms of pain, redness, photophobia and tearing, all suggestive for traumatic iritis. Complete exam including dilated fundus exam rules out accompanying retinal injury



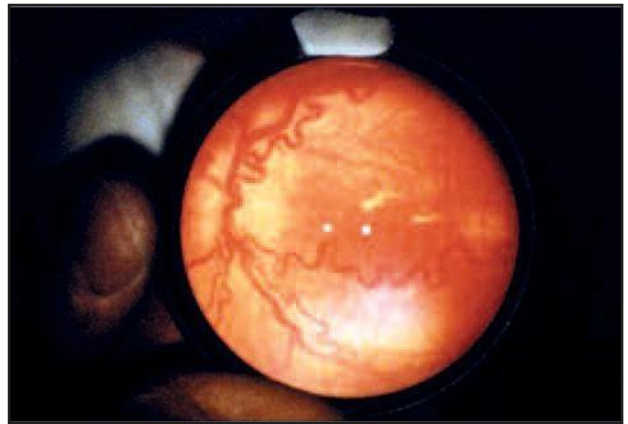
**Fig. 5** Leukocoria in a four-month-old male patient from a congenital cataract. Parent had noted the condition several days earlier.

in the form of detachment or commotion retinae. Cycloplegics and steroids remain the mainstay of treatment, although the use of steroids should be accompanied by an antibiotic if there is an associated corneal abrasion.

Minor superficial abrasions of the lids and adnexa can be treated with topical bacitracin ophthalmic ointment, as skin preparations obtained OTC can irritate the eye if it is rubbed between the lids. All invasions of the skin should be searched for foreign material. Insect bites can result in severe edema of the periocular structures and should be evaluated to rule out potentially necrotizing tissue as the result of spider bites.

Chemical injury may be severely vision disabling, especially with the availability of alkaline household cleaning agents. The container should always be examined by the doctor and pH testing performed.<sup>14</sup> Acid injuries to the cornea form a barrier making penetration of the acid more difficult. Mild acidic burns to the cornea can be treated similarly to corneal abrasions and respond well to this therapeutic management. Alkaline burns (i.e., lye, ammonia) are the most dangerous agents as they penetrate the cornea rapidly.<sup>15</sup> Immediate topical anesthesia is used, followed by sweeping of the conjunctival fornices to remove any undissolved particulate matter prior to copious irrigation. At least one litre of irrigation is recommended, after placement of a pediatric lid speculum.<sup>15</sup> The child/infant may need to be immobilized by parent(s) or staff for this procedure. If fluorescein staining reveals corneal involvement, immediate referral is recommended. Care must be taken to not confuse a 100% corneal epithelial abrasion which appears uniform with non-staining, as Bowman's takes up fluorescein poorly.

Cyanoacrylate ("Super glue") may stick the lashes together, but rarely damage the cornea beyond an abrasion. Lashes may need to be cut to allow the eye to open for a



**Fig. 6** Binocular indirect ophthalmoscopic view of a three-month-old infant with retinopathy of prematurity (ROP). Retinal assessment is vital for infants with sudden acquired strabismus or leukocoria.

complete eye exam. Lashes typically re-grow in 2-3 weeks.

Thermal injuries (e.g., cigarette burn) fortunately are superficial and can be treated like a corneal abrasion.<sup>16</sup> Frequently, the fast eyelid closure will result in first- or second-degree burns of the eyelid skin.<sup>16</sup> First-degree erythema can be treated with topical ointments. Due to the thin eyelid skin, second-degree burns can rapidly progress to third degree and result in lid deformity. Therefore in cases of second-degree burn (blister), referral is suggested. Instillation of a topical analgesic agent (i.e., Voltaren, Bromfenac) may calm down the pediatric patient.

#### NON-ACCIDENTAL TRAUMA

Unfortunately, cases continue to present as a result of inflicted injury. In the infant, children can present with confusing histories of "having fallen from the changing table" with extensive periocular injury and lethargy. Dilated fundus exam may reveal retinal hemorrhages. In any instance of suspected child abuse the examining physician is required by law to immediately contact social services.<sup>17</sup> The child is taken from the guardians until a complete work up is performed, while hospitalized, including retinal consultation, MRI, CT scans and long-bone studies. This approach is taken to prevent any episode of repeat trauma which carries a 50% mortality rate.<sup>18</sup> The AAO position paper can be accessed online and should be downloaded for office referral and in-service training.<sup>17</sup> The triad of intracranial hemorrhage, multi-layered retinal hemorrhages, and/or skeletal fractures, makes the diagnosis of non-accidental trauma highly likely.<sup>18</sup> All of your staff need to be on the alert for such conditions as the initial examining physician is directly liable for any secondary injury to the patient, if appropriate referral is overlooked.<sup>18</sup>

## PEDIATRIC CATARACTS

Cataracts are a common and treatable ocular disorder in children. The reported incidence of infantile cataracts ranges from 1 to 13 per 10,000 live births.<sup>19</sup> The most useful classification of pediatric cataracts is by their location and clinical appearance.

Detection of cataracts is made visually by the pediatrician in the newborn using a direct ophthalmoscope to look for a red reflex in the undilated pupil. Parents sometimes detect cataracts if their location is more anterior (polar cataract) or if they note a change in light reflex in the pupil (leukocoria) (Fig. 5). Utilizing the same technique, the eye care physician can attempt to view the fovea through a suspected cataract in the child. If the examiner can view the fovea through the cataract with an undilated pupil, it is likely that the infant will develop good vision and surgery can be deferred.

Retinoscopy may also be employed in decision-making for cataract referral. If it is possible to determine an accurate retinoscopy through an undilated pupil in the infant with a congenital cataract, it is safe to defer surgery. If, on the other hand, it is not possible to determine an accurate retinoscopy result, surgery may be indicated.

Examination of the posterior segment through a dilated pupil is also important to rule out congenital anomalies (i.e., ROP, tumors, vitreous opacities) (Fig. 6). If visualization of the posterior pole is not possible because of the cataract, ultrasound is another viable option to view the posterior pole. Normal neonates may not develop good fixation and following responses until 2 to 3 months of age so careful clinical examination is the most important determinant in a visually significant cataract in the newborn.<sup>20</sup> Since cataracts may progress, serial examinations in the first several years are important to reassess the visual significance of a congenital cataract.<sup>20</sup>

Amblyopia treatment may be required prior to and after cataract extraction in the treatment of amblyopia, a condition which is a major challenge in many cases of pediatric cataracts. The most profound amblyopia associated with pediatric cataracts is the deprivation type, which is most devastating in eyes with unilateral congenital cataracts.<sup>21</sup> The challenge to the eye care physician is to detect unilateral or bilateral congenital cataracts early which could potentially produce deprivation amblyopia, and to determine if surgery needs to be performed in the early years of life. Partial lenticular opacities may not require surgical intervention until years later if good visual stimulation is maintained in the child's developing eye.

Strabismus is another cause of amblyopia, and is commonly associated with cataracts in the pediatric population. Most, if not all, patients with visually significant unilateral, congenital cataracts have strabismus.<sup>21</sup> The deviation persists even after surgical intervention and post-operative efforts to visually rehabilitate the eye

should be attempted. In children with bilateral cataracts, the prevalence of strabismus is also high, ranging from 40% to 90%.<sup>21</sup> This is especially true if cataract surgery was performed early.<sup>20</sup> Among those patients with strabismus from bilateral cataracts, amblyopia occurs in approximately 50% of cases.<sup>22</sup>

## PEDIATRIC GLAUCOMA

Glaucoma in the pediatric population is uncommon.<sup>23</sup> Once diagnosed, glaucoma control becomes a lifelong goal, considering the myriad patient problems one encounters with adult glaucoma. It has the added complication of having to include parents and care givers into the treatment mix.

Pediatric glaucoma can be divided into two main categories: primary and secondary.<sup>24</sup> The primary group is sub-classified according to the presence or absence of associated systemic or other significant ocular anomalies. The secondary group is classified according to its etiologies.

Key features in the pediatric glaucoma evaluation include the appropriate medical and family history of the child, which can be essential for the diagnosis. The ophthalmic exam should include a general inspection of the external eye to rule out corneal enlargement (megalocornea) and possible opacification. Evaluation of the anterior segment can be achieved with a hand-held biomicroscope or 20 D lens and a light source such as a transilluminator. Additionally, the normal glaucoma and evaluation techniques of tonometry, gonioscopy (which may need to be done under light anesthesia utilizing a direct gonioscopy technique), and fundus examination, which includes retinal nerve fiber layer (RNFL) assessment as well as assessment of the optic nerve head (ONH). In this group, anterior chamber evaluation and tonometry are essential in the care of any pediatric glaucoma patient.

The eye care physician should keep in mind that the differential diagnosis of pediatric glaucoma is that primary congenital glaucoma is a disease of exclusion. The child should have no other systemic or ocular disorders. Sequentially measured elevated intraocular pressures are good evidence of glaucoma.

The medical treatment for children with glaucoma is acetazolamide.<sup>25</sup> Acetazolamide, at doses of 10 to 15 mg/kg/day orally, is safe to use in the short term and reduces the pressure by about one-third. Its use can result in metabolic acidosis and may also be associated with hypernea, diminished appetite and general fatigue symptoms.<sup>25</sup>

Surgically, goniotomy is the most successful procedure for infantile primary congenital glaucoma.<sup>26</sup> If intraocular pressure is still elevated after goniotomy, trabeculotomy is indicated for continued pressure lowering and is a very successful procedure. Patients who are poor candidates for goniotomy or trabeculotomy usually receive implant surgery.



In summary, pediatric glaucoma is an uncommon but important cause of blindness in childhood. Visual prognosis for treated patients with pediatric glaucoma has been improving. However, late diagnosis can result in permanent or severe visual loss.

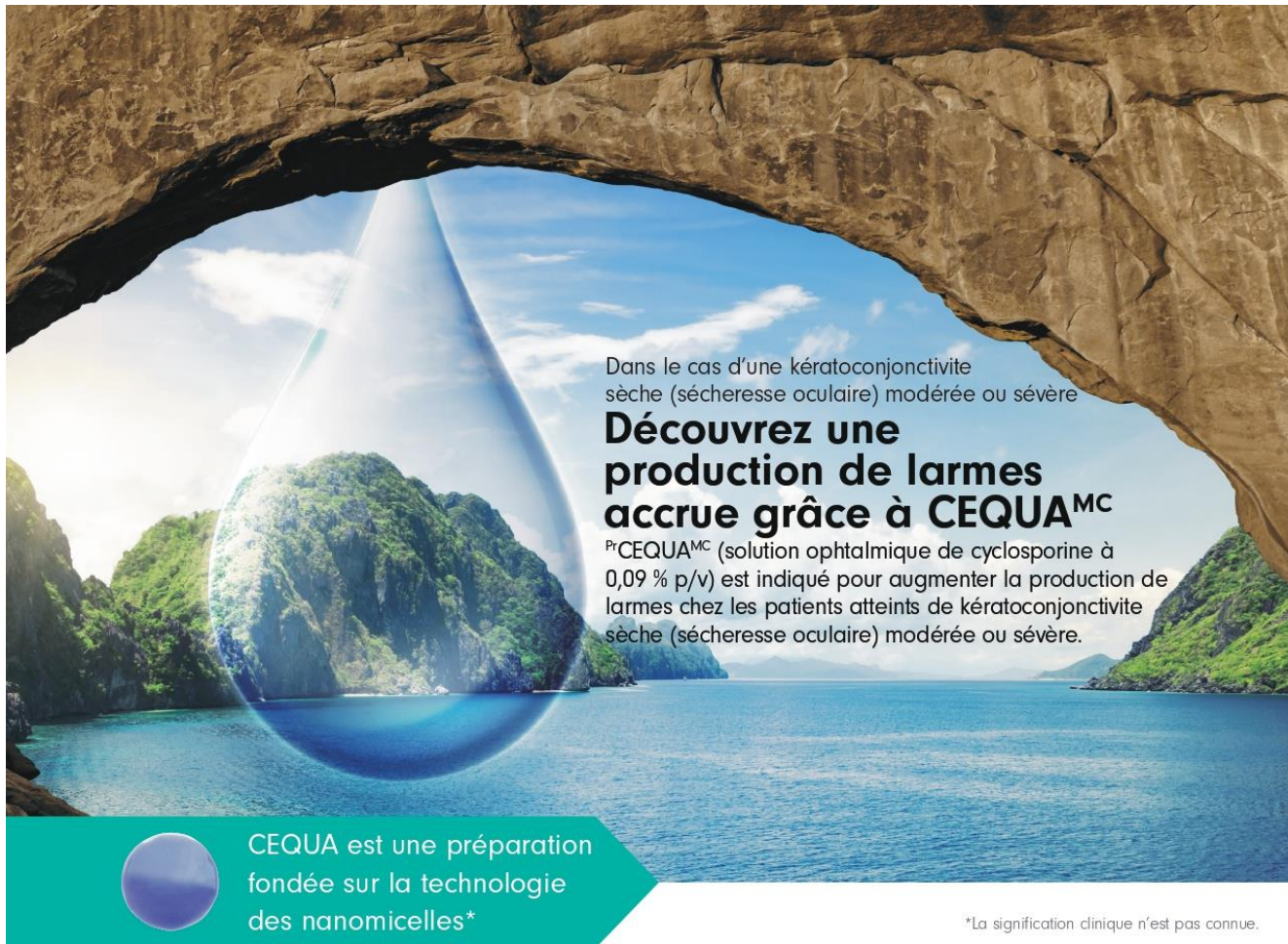
## CONCLUSION

The eye care practitioner plays a vital role in the health and ocular well-being of the pediatric population. Apart from the ability to treat the ocular maladies that present in the office, the ocular physician can also be the first health care provider the child encounters. This can leave a lasting life-long impression on the patient.

In pediatric cases, there are significant differences with respect to examination techniques and reliability of subjective testing, as well as with the types of diseases encountered, their manifestations and their potential for impact on the developing child. The ocular physician may find that with a little patience and reasoning, they may have just found a life-long patient for their practice. □

## REFERENCES


1. Weiss A, Brisner JH, Nazar-Stewart V. Acute conjunctivitis in childhood. *J Ped* 1993; 122: 10-14.
2. Slater LN, Welch DF, Bartonella, including CAT-scratch disease: In: Mandell GL, Bennett JE, Dolin R, eds. *Principles and Practice of Infectious Disease*, 6th ed. Philadelphia: Churchill Livingstone Elsevier, 2005; Chap. 232 pp. 1741-1758.
3. Jerris RC, Regnery RL. Will the real agent of cat-scratch fever please stand up. *Annu Rev Microbiol*. 1996; 50: 707-725.
4. Teoh DL, Reynolds S. Diagnosis and management of pediatric conjunctivitis. *Pediatric Emerg Care* 2003; 19: 48-55.
5. Chadberry IE, Schnitzler P, Geiss HK, et al. An outbreak of epidemic keratoconjunctivitis in a pediatric unit due to adenovirus type 8. *Infection Common Hosp Epidemiology* 2003; 24: 514-519.
6. Avunduk AM, Avunduk MC, Dayanir V, et al. Pharmacological mechanism of topical lodoximide treatment in vernal keratoconjunctivitis. *Ophthalmic Res* 1998; 30: 37-43.
7. Jackson WB. Blepharitis: Current strategies for diagnosis and management. *Can J Ophthalmol* 2008; 43(2): 170-179.
8. Darville T. Chlamydial trachomatis infections in neonates and young children. *Semin Pediatric Infectious Disease* 2005; 16: 235-244.
9. Girner LB. Periorbital and orbital infections. *Pediatric Infectious Disease J* 2002; 21: 1157-1158.
10. Liesegang TJ. Epidemiology of ocular herpes simplex: Natural history in Rochester, Minn. 1950 through 1982. *Arch Ophthalmol* 1989; 107: 1160-1165.
11. Dohil MA, Lin P, Lee J. et al. The epidemiology of Molluscum Contagiosum in children. *J Am Acad Dermatol* 2006; 54: 47-54.
12. Vinger PF. Ocular injuries and appropriate protection. Focal Points: clinical modules for ophthalmologists. *Am Acad Ophthalmol* 1997; 15: 8.
13. La Sage N, Verreault R, Rochette L. Efficiency of eye patching for traumatic corneal abrasions: a controlled clinical trial. *Ann Emergency Med* 2011; 38: 129-134.
14. Ramasubramanian A, Johnston S. Neonatal Eye Disorders Requiring Ophthalmology Consultation. *NeoReviews* 2011;12; e216-e222.
15. Ikeda N, Hayasaka S, Hayasaka S, Watanabe K. Alkali burns of the eye: effect of immediate copious irrigation with tap water on their severity. *Ophthalmologica* 2006; 220: 225-228.
16. Kuckelkorn R, Schrange N, Keller G, et al. Emergency treatment of chemical and thermal eye burns. *Acta Ophthalmol Scand* Feb 2002; 80(1): 4-10.
17. Levin A, Forbes B, Alexander R, Jenny C. Information Statement: Abusive Head Trauma, Shaken Baby Syndrome. American Academy of Ophthalmology. June 2010 San Francisco, California. [www.aao.org](http://www.aao.org)
18. McCabe CF, Donahue SP. Prognostic indicators for vision and mortality in shaken baby syndrome. *Arch Ophthalmol* 2000; 118: 373-377.
19. San Giovanni JP, Chew EY, Reed GF, et al. Infantile cataract in the collaborative perinatal project: prevalence and risk factors. *Arch Ophthalmol* 2001; 120: 1559-1565.
20. Inavi GM, Schnall BM, Lehman SS, et al. Visual outcome and success of amblyopia treatment in unilateral small posterior lens opacities and lenticonus initially treated non-surgically. *JAAPOS* 2005; 9: 449-454.
21. Cheng KP, Hiles DA, Biglaw AW, et al. Visual results after early surgical treatment of unilateral congenital cataracts. *Ophthalmology* 1991; 98: 903-910.
22. Gelbart SS, Hoyt CS, Jastrebski G, et al. Long-term visual results in bilateral congenital cataracts. *Am J Ophthalmol* 1982; 93:615-621.
23. Walton DS, Katsavounidou G. Newborn primary congenital glaucoma 2005 update. *J Pediatric Ophthalmol Strabismus* 2005; 42: 333-341.
24. Ho CL, Walton DS. Primary megalocornea: clinical features for differentiating from infantile glaucoma. *J Pediatr Ophthalmol Strabismus* 2004; 41: 11-17.
25. Wayman LC, Larson LI, Maus TL, et al. Additive effective of dorzolamide on aqueous humor flow in patients receiving long-term treatment with timolol. *Arch Ophthalmol* 1988; 116: 1438-1440.
26. McPherson SD Jr, Berry DP. Goniotomy vs external trabeculotomy for developmental glaucoma. *Am J Ophthalmol* 1983; 95: 427-431.



Dans le cas d'une kératoconjonctivite sèche (sécheresse oculaire) modérée ou sévère

## Découvrez une production de larmes accrue grâce à CEQUA<sup>MC</sup>

Pr CEQUA<sup>MC</sup> (solution ophtalmique de cyclosporine à 0,09 % p/v) est indiqué pour augmenter la production de larmes chez les patients atteints de kératoconjonctivite sèche (sécheresse oculaire) modérée ou sévère.

 CEQUA est une préparation fondée sur la technologie des nanomicelles\*

\*La signification clinique n'est pas connue.

### Usage clinique :

**Enfants (< 18 ans) :** L'efficacité et l'innocuité de CEQUA n'ont pas été établies chez les enfants. Santé Canada n'a donc pas autorisé d'indication pour cette population.

**Personnes âgées (> 65 ans) :** Dans l'ensemble, aucune différence n'a été observée sur le plan de l'innocuité ou de l'efficacité entre les patients âgés et les patients adultes plus jeunes.

### Contre-indications :

- Patients qui présentent une hypersensibilité à ce médicament ou à l'un des composants du produit (y compris les ingrédients non médicinaux) ou du contenant
- Patients atteints d'infections oculaires ou périoculaires évolutives ou soupçonnées
- Patients atteints d'affections oculaires ou périoculaires malignes ou précancéreuses

### Mises en garde et précautions pertinentes :

- Destiné à un usage ophtalmique topique seulement
- Il convient de résoudre les infections oculaires ou périoculaires existantes ou soupçonnées

avant l'instauration d'un traitement par CEQUA. Si une infection se produit pendant le traitement, l'administration de CEQUA doit être interrompue jusqu'à ce que l'infection ait été enrayée.

- Il faut déconseiller aux patients de conduire un véhicule et d'utiliser des machines jusqu'à ce que leur vision soit redevenue normale après l'administration de CEQUA.
- CEQUA n'a pas été étudié chez des patients ayant des antécédents de kératite herpétique, de maladie des glandes lacrymales en phase terminale, de kératoconjonctivite sèche (KCS) causée par la destruction des cellules caliciformes conjonctivales comme dans le cas d'une carence en vitamine A, ou de tissu cicatriciel comme dans le cas d'une pemphigoïde cicatricielle, de brûlures causées par des produits alcalins, du syndrome de Stevens-Johnson, d'un trachome ou d'une exposition au rayonnement.
- Il faut surveiller de près les patients atteints d'une kératite grave.
- Risque de blessure et de contamination oculaires

- CEQUA ne doit pas être administré pendant que le patient porte des lentilles cornéennes.
- Infections et tumeurs locales : Une surveillance régulière est recommandée lorsque CEQUA est utilisé à long terme.
- Réactions d'hypersensibilité
- Les effets de CEQUA n'ont pas été étudiés chez des patients atteints d'insuffisance rénale ou hépatique.
- CEQUA est déconseillé pendant une grossesse, sauf si les avantages l'emportent sur les risques.
- Il faut faire preuve de prudence lors de l'administration de CEQUA aux femmes qui allaitent.

### Pour de plus amples renseignements :

Veuillez consulter la monographie de CEQUA à l'adresse [https://pdf.hres.ca/dpd\\_pm/00060038.pdf](https://pdf.hres.ca/dpd_pm/00060038.pdf) pour des renseignements importants non abordés ici concernant les effets indésirables, les interactions médicamenteuses et la posologie. Vous pouvez aussi obtenir la monographie du produit en communiquant avec notre Service médical au numéro sans frais 1 844 924-0656.

**RÉFÉRENCE :** Monographie de CEQUA<sup>MC</sup> actuelle, Sun Pharma Global FZE.



## INSTRUCTIONS POUR OBTENIR UN CREDIT UFC

Pour obtenir un crédit UFC pour ce cours remplissez le questionnaire ci-dessous et renvoyez-le soit en ligne, par courriel ou par courrier ordinaire. Le coût de la notation de chaque quiz est de 25,00 \$ (plus taxes) et vous serez facturé via PayPal après avoir reçu votre certificat de crédit UFC. Ce cours expirera pour le crédit UFC le 31 mars 2024. Veuillez ne pas le soumettre après cette date.

**En ligne :** Accéder le questionnaire en ligne en cliquant ci-dessous à l'endroit indiqué. Complétez le test à l'écran, puis cliquez sur le bouton «SUBMIT» à la fin du quiz pour le soumettre à la notation. Si vous rencontrez un problème pour soumettre le test en ligne, soumettez le questionnaire par courriel ou par courrier ordinaire. Vous serez facturé via PayPal pour 25,00 \$ plus taxes après avoir reçu votre certificat de crédit UFC.

**CLIQUEZ [ICI](#) POUR ACCÉDER AU QUESTIONNAIRE EN LIGNE**

**Par courriel :** Inscrivez vos réponses au questionnaire de test (comme suit : 1-a, 2-c, 3-d... etc.) et incluez également votre nom, votre adresse postale et votre numéro de licence professionnelle, et envoyez-les à [info@optomed.ca](mailto:info@optomed.ca). Vous serez facturé via PayPal pour 25.00\$ plus taxes après avoir reçu votre certificat de créditUFC.

**Par courrier ordinaire:** Inscrivez vos réponses au questionnaire de test (comme suit : 1-a, 2-c, 3-d... etc.) plus votre nom, votre adresse postale et votre numéro de licence professionnelle, et postez-les à Optomed Québec 421- 5885 Marc Chagall, Montreal QC H4W 0C1. Vous serez facturé via PayPal pour 25.00\$ plus taxes après avoir reçu votre certificat de crédit UFC.